

Available online at www.sciencedirect.com

ScienceDirect

journal homepage: www.ejcancer.com

Review

European consensus-based interdisciplinary guideline for melanoma. Part 2: Treatment - Update 2022



Claus Garbe ^{a,*}, Teresa Amaral ^a, Ketty Peris ^{b,c}, Axel Hauschild ^d, Petr Arenberger ^e, Nicole Basset-Seguin ^f, Lars Bastholt ^g, Veronique Bataille ^h, Veronique del Marmol ⁱ, Brigitte Dréno ^j, Maria C. Fagnoli ^k, Ana-Maria Forsea ^l, Jean-Jacques Grob ^m, Christoph Hoeller ⁿ, Roland Kaufmann ^o, Nicole Kelleners-Smeets ^p, Aimilios Lallas ^q, Celeste Lebbé ^f, Bodhan Lytvynenko ^r, Josep Malvehy ^s, David Moreno-Ramirez ^t, Paul Nathan ^u, Giovanni Pellacani ^v, Philippe Saiag ^w, Alexander J. Stratigos ^x, Alexander C.J. Van Akkooi ^y, Ricardo Vieira ^z, Iris Zalaudek ^{aa}, Paul Lorigan ^{ab} On behalf of the European Dermatology Forum (EDF), the European Association of Dermato-Oncology (EADO), and the European Organization for Research and Treatment of Cancer (EORTC)

^a Center for Dermatooncology, Department of Dermatology, Eberhard Karls University, Tuebingen, Germany

^b Institute of Dermatology, Università Cattolica, Rome, Italy

^c Fondazione Policlinico Universitario A. Gemelli – IRCCS, Rome, Italy

^d Department of Dermatology, University Hospital Schleswig-Holstein (UKSH), Campus Kiel, Kiel, Germany

^e Department of Dermatovenereology, Third Faculty of Medicine, Charles University, Prague, Czech Republic

^f Université Paris Cite, AP-HP, Department of Dermatology INSERM U 976 Hôpital, Saint Louis Paris France

^g Department of Oncology, Odense University Hospital, Odense, Denmark

^h Twin Research and Genetic Epidemiology Unit, School of Basic & Medical Biosciences, King's College London, London, SE1 7EH, United Kingdom

ⁱ Department of Dermatology, Erasme Hospital, Université Libre de Bruxelles, Brussels, Belgium

^j Dermatology Department, CHU Nantes, CIC 1413, CRCINA, University Nantes, Nantes, France

^k Dermatology, Department of Biotechnological and Applied Clinical Sciences, University of L'Aquila, L'Aquila, Italy

^l Dermatology Department, Elias University Hospital, Carol Davila University of Medicine and Pharmacy Bucharest, Romania

^m University Department of Dermatology, Marseille, France

ⁿ Department of Dermatology, Medical University of Vienna, Austria

^o Department of Dermatology, Venereology and Allergology, Frankfurt University Hospital, Frankfurt, Germany

^p Department of Dermatology, Maastricht University Medical Center+, Maastricht, Netherlands

DOI of original article: <https://doi.org/10.1016/j.ejca.2022.03.008>.

* Corresponding author: Center for Dermatooncology, Department of Dermatology, Eberhard Karls University, Liebermeisterstr. 25 72076 Tuebingen, Germany. Fax: +49 7071 29 5187.

E-mail address: claus.garbe@med.uni-tuebingen.de (C. Garbe).

<https://doi.org/10.1016/j.ejca.2022.04.018>

0959-8049/© 2022 The Authors. Published by Elsevier Ltd. This is an open access article under the CC BY-NC-ND license (<http://creativecommons.org/licenses/by-nc-nd/4.0/>).

^q First Department of Dermatology, Aristotle University, Thessaloniki, Greece

^r Shupyk National Medical Academy of Postgraduate Education, Kiev, Ukraine

^s Melanoma Unit, Department of Dermatology, Hospital Clinic, IDIBAPS, Barcelona, Spain

^t Medical-&-Surgical Dermatology Service, Hospital Universitario Virgen Macarena, Sevilla, Spain

^u Mount-Vernon Cancer Centre, Northwood United Kingdom

^v Dermatology Unit, University of Modena and Reggio Emilia, Modena, Italy

^w University Department of Dermatology, Université de Versailles-Saint Quentin en Yvelines, APHP, Boulogne, France

^x First Department of Dermatology, University of Athens School of Medicine, Andreas Sygros Hospital, Athens, Greece

^y Melanoma Institute Australia, The University of Sydney, and Royal North Shore and Mater Hospitals, Sydney, New South Wales, Australia

^z Department of Dermatology and Venereology, Centro Hospitalar Universitário de Coimbra, Coimbra, Portugal

^{aa} Dermatology Clinic, Maggiore Hospital, University of Trieste, Trieste, Italy

^{ab} The University of Manchester, Oxford Rd, Manchester, M13 9PL, United Kingdom

Available online 24 May 2022

KEYWORDS

Cutaneous melanoma;
Tumor thickness;
Excisional margins;
Sentinel lymph node dissection;
Interferon- α ;
Adjuvant treatment;
Metastasectomy;
Systemic treatment

Abstract A unique collaboration of multidisciplinary experts from the European Dermatology Forum (EDF), the European Association of Dermato-Oncology (EADO), and the European Organization of Research and Treatment of Cancer (EORTC) was formed to make recommendations on cutaneous melanoma diagnosis and treatment, based on the systematic literature reviews and the experts' experience. Cutaneous melanomas are excised with one to 2-cm safety margins. Sentinel lymph node dissection shall be performed as a staging procedure in patients with tumor thickness ≥ 1.0 mm or ≥ 0.8 mm with additional histological risk factors, although there is as yet no clear survival benefit for this approach. Therapeutic decisions in stage III/IV patients should be primarily made by an interdisciplinary oncology team ("tumor board"). Adjuvant therapies can be proposed in stage III/completely resected stage IV patients and are primarily anti-PD-1, independent of mutational status, or alternatively dabrafenib plus trametinib for BRAF mutant patients. In distant metastases (stage IV), either resected or not, systemic treatment is always indicated. For first-line treatment particularly in BRAF wild-type patients, immunotherapy with PD-1 antibodies alone or in combination with CTLA-4 antibodies shall be considered. In stage IV melanoma with a BRAF-V600 E/K mutation, first-line therapy with BRAF/MEK inhibitors can be offered as an alternative to immunotherapy. In patients with primary resistance to immunotherapy and harboring a BRAF-V600 E/K mutation, this therapy shall be offered as second-line therapy. Systemic therapy in stage III/IV melanoma is a rapidly changing landscape, and it is likely that these recommendations may change in the near future.

© 2022 The Authors. Published by Elsevier Ltd. This is an open access article under the CC BY-NC-ND license (<http://creativecommons.org/licenses/by-nc-nd/4.0/>).

1. Surgical therapy

1.1. General principles

The treatment of primary melanoma is surgical excision [1–3]. An excisional biopsy with a minimum clinical margin (1–3 mm) is preferred, both to give the dermatopathologist/pathologist an optimal specimen and allow evaluation of the excision margins for residual tumor. Incisional biopsies should not be performed when an excisional biopsy is technically

possible. Such procedures may result in a diagnostic error because of incomplete sampling and may compromise the analysis of architectural features or the estimation of Breslow thickness. On occasions, incisional biopsy may be necessary to confirm the diagnosis, such as when dealing with a large head and neck lentigo maligna or with acral or mucosal melanoma. Large studies have shown no evidence that either incisional or shaving biopsies worsen prognosis as compared with immediate complete excisional biopsy [4–6].

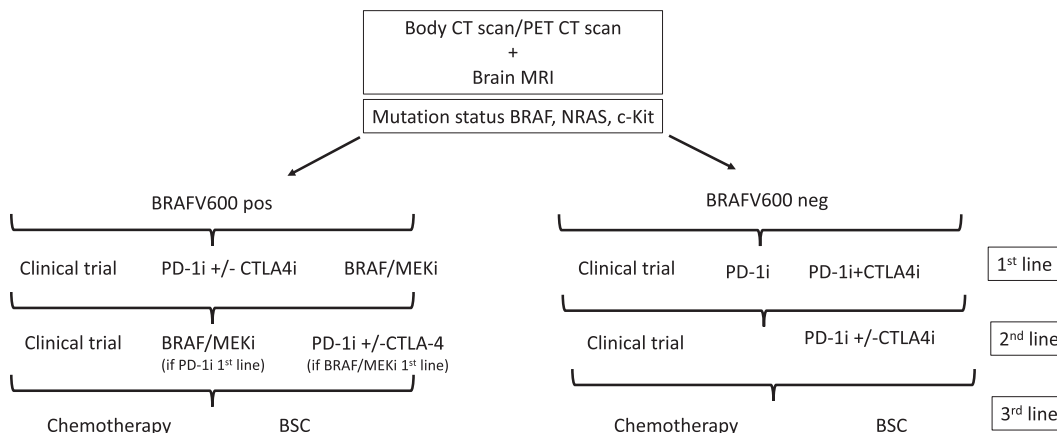


Fig. 1. Proposed algorithm for the treatment of stage IV melanoma; in the first-line setting, the treatment priority should be read from left to right.

Recommendation 12 (numbers continued from Part 1)

Primary excision	Consensus-based recommendation
GCP	When melanoma is suspected, the whole lesion should be completely excised with a narrow (1–3 mm) margin in order to perform a histological diagnosis. Incisional biopsies can be performed on large lesions such as lesions on the face (e.g., lentigo maligna), acral lesions, and on the genitalia. Consensus rate: 100%

Recommendation 13

Avoidance of non-surgical treatments	Consensus-based recommendation
GCP	If melanoma cannot be excluded, blind destructive treatments such as laser, cryotherapy, or topical drugs shall not be performed. Consensus rate: 100%

1.2. Primary melanoma

Excision with a safety margin remains a standard of care in melanoma patients. The current recommendations are based on both prospective, randomized studies and international consensus guidelines [1,7–11]. A randomized, open-label multicenter clinical trial comparing 1 cm vs. 3 cm margins in patients with primary cutaneous melanoma on the trunk and limbs suggested that a 1 cm excision margin is inadequate for cutaneous melanoma with Breslow thickness greater than 2 mm [12]. A meta-analysis showed that there is a statistically significant worse melanoma-specific survival (MSS) with narrow (1–3 cm) than with wider margins (3–5 cm) with no treatment effect on recurrence-free survival (RFS) [13]. However, with regard to MSS, only four trials were eligible, and the hazard ratio (HR) in favor of wider margins was largely affected by the positive trial

of Hayes et al (3 cm vs. 1 cm) [12], while another study comparing 4 cm vs. 2 cm did not show any statistical difference in thicker melanomas [14]. Only recently, a further meta-analysis involving 4579 patients’ data from seven randomized clinical trials revealed no significant difference between narrow (1–2 cm) and wide (3–5 cm) excision margins in locoregional or distant recurrence, metastasis, death, or death due to melanoma [15]. Moreover, the usefulness of margins above 1 cm still remains unclear in patients with stage II melanoma (pT2b–pT4b, AJCC 8th edition). An ongoing clinical trial comparing 1 cm vs. 2 cm margins (MelMart-II) is expected to offer valuable data about this.

Even though a slight variation is observed among guidelines, margins wider than 2 cm are not recommended even in cases of thick primary tumors. The recommendations below are in concordance with the American, UK, and Australian references. In invasive melanomas, the depth of excision should include the subcutaneous tissue. The definitive surgical excision should be performed preferentially within 4–6 weeks of initial diagnosis and simultaneously with the SLNB.

Recommendation 14

Safety margins for secondary excision (re-excision)	Evidence-based recommendation
GCP	In the case of primary melanoma, a subsequent excision should be performed in order to minimize the risk of local recurrences. The following safety peripheral surgical margins* should be considered: in situ: 5 mm ≤2 mm tumor thickness: 1 cm >2 mm tumor thickness: 2 cm Larger excisions are not recommended. Guideline adaptation [16,17] Consensus rate: 100%

*Margins are to be measured clinically and not pathologically; the initial excision margin should be included in the total safety margins definition.

Recommendation 15

Safety margins for secondary excision (re-excision) in special anatomic locations	Evidence-based recommendation
GCP	Narrower margins for re-excision may be exceptionally considered for special anatomic locations in order to preserve function, maintain cosmesis, and to allow reconstruction, particularly in facial, acral, and genital lesions. Guideline adaptation [16,17] Consensus rate: 100%

1.3. Lentigo maligna

Lentigo maligna is a slowly growing melanoma in situ, which occurs typically in UV-exposed areas like the face [18]. A Cochrane review about interventions in melanoma in situ failed to find randomized clinical trials of surgical interventions aiming to optimize margin control (square method, perimeter technique, “slow Mohs”, staged radial sections, staged “mapped” excisions, or Mohs micrographic surgery), which are the most widely used interventions recommended as first-line therapy [19]. A retrospective study including patients with lentigo maligna melanoma treated through staged surgery with immunohistopathological control of lateral margins showed a higher clearance and a lower recurrence rate than wide excisions [20]. A single-center retrospective study compared conventional surgical excision and “slow Mohs surgery” for patients with lentigo maligna melanoma. This study concluded that surgical margins of 0.5 cm are inadequate for the treatment of a considerable number of lesions on the head, particularly if these are recurrent. “Slow Mohs” using routinely stained paraffin-embedded sections was shown to be the treatment of choice in such cases, particularly for recurrent lesions or lesions with poorly defined borders or possible subclinical extension [21]. Because of unpredictable subclinical extension of the adjacent intraepidermal component, the management of lentigo maligna melanoma may range from a 5 mm margin to wider margins (up to 10 mm). For larger lentigo maligna and lentigo maligna melanoma, microscopically controlled surgery is a recommended option and is usually performed following any of the technical variations developed (frozen section Mohs micrographic surgery, paraffin-embedded, “slow Mohs”, and 3D-histology) [21,22].

As for non-surgical interventions, high-quality evidence does not support the use of imiquimod as primary therapy in non-selected cases [19]. However, several retrospective analyses and phase II trials support a role for topical imiquimod as a potential alternative to surgery in selected cases not eligible for surgery or radiotherapy [23], as well as for incompletely excised tumors or as an adjuvant option for those treated through

narrow margins [24]. Recently, a 95% cure rate after a mean follow-up of three years has been reported with adjuvant imiquimod following conventional surgery with narrow margins [25]. The complete response rate to imiquimod treatment is in the range of 75%–88% [26–28]. Pre-treatment mapping biopsies or in vivo reflectance confocal microscopy can be used to assess the extent of the lesion [29].

1.4. Acral and mucosal melanomas

Lentiginous acral and mucosal melanomas have often poorly defined margins and are multifocal leading to discrepancies between the clinically visible and histopathologic margins. Local recurrences are more frequent. Therefore, surgical excision is usually attempted with increased safety margins (at least 1 cm) or by narrow margins with micrographic control (e.g., Mohs’ technique and variants) [30–32]. The micrographic technique is intended to conserve tissue, especially on the hands and feet.

Recommendation 16

Microscopically controlled surgery	Consensus-based recommendation
GCP	In some melanoma subtypes, such as lentigo maligna melanoma, genital and acral melanomas, and microscopically controlled surgery can be used to spare tissue and ensure complete resection. Consensus rate: 90%; 2 abstentions

1.5. Sentinel lymph node biopsy

The sentinel lymph node biopsy (SLNB) was introduced in order to allow the evaluation of the first draining lymph node(s) in the regional lymphatic system avoiding the surgical morbidity from unnecessary elective lymph node dissections [33]. SLNB is a staging procedure, appropriate for patients in whom neither palpation nor lymph node sonography has suggested the presence of lymph node metastases. SLNB involvement is an independent prognostic factor for MSS and is considered a standard staging procedure [34]. In addition, a positive sentinel lymph node (SLN) will upstage patients with clinically negative nodes and make them eligible for adjuvant systemic therapy. As all the adjuvant trials have selected the patients on the basis of the positivity of SLNB, the SLNB status is required for the new adjuvant options. Multicenter studies have shown that despite a slight increase in RFS in patients undergoing SLNB, there is no impact on overall survival (OS) [35–37].

In melanoma ≥ 1 mm thickness, recent guideline updates recommend SLNB as a standard procedure to be offered to patients with primary melanoma with Breslow thickness ≥ 1.0 mm or ≥ 0.8 mm with additional risk

factors (ulceration, ≥ 1 mitosis/mm², microsatellites, etc.) [38,39].

Recommendation 17

Sentinel lymph node biopsy	Evidence-based recommendation
Level of recommendation A	For a correct stage classification and treatment decision, a sentinel lymph node biopsy shall be offered in patients with tumor thickness ≥ 1.0 mm or ≥ 0.8 mm with additional histological risk factors.
Level of evidence: 1a	De novo literature research [40,41] Consensus rate: 90%

1.6. Procedure in patients with negative SLN

No further lymph node surgery is required.

1.7. Procedure in patients with micro-metastases in SLN

Complete lymph node dissection (CLND) has previously been routinely offered to patients having micro-metastasis of the SLN. The results of the German Dermatologic Cooperative Oncology Group (DeCOG) and Multicenter Selective Lymphadenectomy Trial (MSLT-II) clinical trials led to the revision of the role of lymphadenectomy in patients with SLN metastasis. In patients with microscopic SLN metastases, both studies failed to show a survival difference between CLND and observation. In the DeCOG study, 68% of patients in the observation arm and 65% in the CLND arm were free of distant metastases after five years of follow-up [42,43]. In the MSLT-II, 86% of the patients in both study groups (CLND or observation) were alive after three years [37]. Moreover, in the MSLT-II study, the percentage of patients with non-sentinel-node metastases was 20% at five years. Consequently, 80% of the CLND performed might have been avoided [37].

Considering the previous results, in patients with SLN micro-metastasis, CLND shall be abandoned [38]. Additionally, recent retrospective studies have shown that adjuvant therapy is offering similar outcomes in patients with microscopic nodal metastases not undergoing CLND than those achieved after CLND in clinical trial settings [44,45]. For information regarding adjuvant systemic therapy in stage III melanoma please refer to section 3 of this guideline.

Recommendation 18

Management of micro-metastasis	Evidence-based recommendation
Level of recommendation A	In patients with sentinel lymph node micro-metastasis, complete lymphadenectomy shall no longer be performed. There is an indication for adjuvant systemic therapy.
Level of evidence: 1a	De novo literature research [37,42,43] Consensus rate: 100%

1.8. Clinically identified lymph node metastases

If lymph node metastases are diagnosed clinically or by imaging techniques (including ultrasound), therapeutic lymph node dissection (TLND) is considered standard therapy [38,46].

In patients with nodal metastases detected clinically or by imaging, neoadjuvant therapy is a novel approach currently under research and with promising results observed in phase II studies. However, practice-changing studies have not been published, yet, making TLND the first-line therapy for patients with resectable nodal disease.

Recommendation 19

Lymphadenectomy in regional lymph node metastases	Consensus-based recommendation
GCP	If regional lymph node macro-metastases have been detected clinically or by imaging, complete lymphadenectomy shall be offered, in the absence of in-transit and distant metastasis. Consensus rate: 100%

1.9. Satellite and/or in-transit metastases

Depending on the number, size, and location of satellite and in-transit metastases, different options include surgery or other destructive therapies such as cryotherapy, laser therapy, electrochemotherapy, and radiotherapy. Systemic therapies with anti-PD-1 immunotherapy, targeted therapy, intralesional immunotherapy (talimogene laherparepvec [T-VEC] [47]), or IL-2 can be used. Topic therapy with imiquimod is also possible. Finally, isolated limb perfusion with melphalan \pm tumor necrosis factor (TNF) might be considered [48,49].

1.10. Distant metastases

If technically feasible and reasonable (oligometastatic disease), complete surgical removal of distant metastases may be an option for selected patients. These include those with a long disease-free interval and with tumor markers LDH and protein S100B in the normal range. Nevertheless, these patients are also those who better respond to systemic therapies [50]. Many studies show that excision of solitary or few metastases can be associated with a favorable outcome for stage IV patients [51–54]. These patients are now eligible for adjuvant systemic therapy after resection of stage IV oligometastatic disease.

The possibility of neoadjuvant therapy followed by surgical excision of metastatic lesions can be considered. Stereotactic radiosurgery (SRS) is also an established treatment in this clinical situation [55].

There is no evidence that debulking procedures improve survival. In some circumstances, there is a value for palliation of symptoms, or if they then allow patients to receive effective systemic therapy.

Recommendation 20

Surgical treatment of distant metastases	Evidence-based recommendation
Level of recommendation C	In case of oligometastatic disease, complete resection or other destructive procedures can be considered. These can also be considered as a palliative procedure. Guideline adaptation [16,17] Consensus rate: 100%

2. Radiotherapy

2.1. Primary melanoma

Radiotherapy of the primary tumor is rarely indicated. However, in elderly or frail patients or where the surgical procedure will lead to severe disfigurement, radiotherapy can be applied with curative intent. This could be considered for lentigo maligna fulfilling these criteria [56].

2.2. Regional lymph nodes

There is no established role for adjuvant radiotherapy of draining lymph nodes after excision of the primary melanoma. Adjuvant radiotherapy after lymphadenectomy has been evaluated in a randomized clinical trial [57], proving the efficacy of radiotherapy in terms of increased locoregional control, but with no impact on survival. Furthermore, the increased locoregional control was accompanied by significant toxicity, with 22% of the patients receiving radiotherapy, developing grade 3–4 toxicity [58].

2.3. Oligometastatic disease

In patients with oligometastatic disease, ablative (SRS or equivalent) radiotherapy represents a treatment alternative to surgery in cases where surgical access is associated with a high risk of significant surgical complications.

2.4. Skin metastases

In-transit metastases, which are too extensive for a surgical approach, may be controlled by radiotherapy alone [59].

2.5. Bone metastases

Radiotherapy is effective to palliate patients with bone metastases. The response rate (complete response and

partial symptom control) is 67–85% [60–63]. The major indications for radiotherapy in these cases are pain, loss of structural stability (fracture risk), and compression of the spinal canal with or without neurological symptoms.

2.6. Brain metastases

Melanoma has a marked propensity to metastasize to the brain. Systemic treatment strategies for brain metastases with high response rates combined with a short time to response using combination immunotherapy [64,65] or targeted therapies [180] led to renewed considerations on how to plan the optimal treatment of melanoma patients with brain metastases.

Preclinical evidence has suggested a positive effect of the combination of immunotherapy and radiotherapy [66,67], and a number of clinical trials are currently in progress evaluating the possible additive effect of this combination or the combination of radiotherapy and BRAF + MEK inhibitors in BRAF mutated melanomas. Recent publications support the concomitant use immunotherapy and stereotactic radiosurgery [SRT] [68–70]. A recent review concludes that the combination of radiotherapy and targeted therapy is safe provided a short drug holiday is introduced [71].

The literature provides only limited evidence for the use of radiotherapy in the treatment of brain metastases [72]. Whole brain radiotherapy (WBRT) may cause serious long-term cognitive toxicity and therefore increased focus on SRS has emerged [73]. Clinical trials have shown increased local control in patients with 1–10 brain metastases using adjuvant SRS after surgery [74]. WBRT is no longer a standard of care for melanoma patients, because it is widely an ineffective and toxic treatment.

3. Adjuvant therapy

3.1. General principles

Adjuvant therapy is offered to patients without evidence of macroscopic metastases but at a high risk of having microscopic metastases. Historically, adjuvant therapy with interferon alpha was used in patients with tumors thicker than 1.5 mm. More recently, checkpoint inhibitors and targeted therapy have been evaluated in resected stage III and stage IV disease. Prolonged RFS and distant metastases free survival (DMFS) in stage III melanoma has been reported for adjuvant therapy with ipilimumab [75], nivolumab [76], pembrolizumab [99] and for therapy with dabrafenib and trametinib in patients with BRAF mutated melanoma [77]. Data demonstrating a significant impact on OS have been reported for ipilimumab [78] and for dabrafenib and trametinib. Recently, early data for adjuvant therapy with pembrolizumab in resected stage IIB and IIC

melanoma also showed a significant improvement in RFS [79]. In addition, the combination of dose modified ipilimumab and nivolumab was tested in a randomized phase III trial in stage III–IV melanoma and the standard dose combination therapy in a randomized phase II study in resected stage IV melanoma without evidence of disease following surgery or radiotherapy [80,81].

3.2. Adjuvant immunotherapy with interferon- α

Interferon- α was the first substance in the adjuvant therapy of melanoma to have shown a significant improvement of disease-free survival and in some prospective randomized trials, also an impact on OS, albeit with significant toxicity [82–94]. Based on the superior data for adjuvant therapy with PD-1 or BRAF/MEK inhibitors (see below), interferon- α should not be used anymore as a first-line option for adjuvant therapy in this patients' group.

3.3. Adjuvant immunotherapy with CTLA-4 or PD-1 antibodies in stage III and resected stage IV disease

Based on its successful use in unresectable metastatic melanoma, PD-1-based immunotherapy was evaluated in the adjuvant treatment of completely resected high-risk primary or locoregional or distant metastatic patients. The following adjuvant immunotherapy trials were conducted (see also Table 1):

Ipilimumab: EORTC 18071/CheckMate 029 [75] compared the CTLA-4 blocking antibody ipilimumab 10 mg/kg given every three weeks for the first 12 weeks followed by an infusion every 12 weeks for up to three years vs. placebo in patients with stage IIIA (>1 mm)/B/C (AJCC 7th edition) [95]. The final data of this trial have been published. With a median OS follow-up of 6.9 years, the RFS (HR 0.75, 95% confidence interval 0.63–0.88; $P < 0.001$), DMFS (HR 0.76, 0.64–0.90;

$P = 0.002$), and OS (HR 0.73, 0.60–0.89; $P = 0.002$) benefit observed in the ipilimumab group was durable with an 8.7% absolute difference at seven years for OS [96]. Adjuvant ipilimumab 10 mg/kg was associated with immune-related adverse events (irAEs) in 94% of the patients, and 5 patients died. Concerns about toxicity resulted in limited uptake of this treatment, which was approved by the US-Food and Drug Administration (FDA) and not by European Medicines Agency (EMA).

Nivolumab: Based on the results of EORTC 18071 trial, adjuvant therapy with nivolumab 3 mg/kg every two weeks for one year was compared to ipilimumab 10 mg/kg in the CheckMate 238 trial [76] in patients with completely resected stage IIIB/C-IV (AJCC 7th edition) [95]. Recently presented five-year results confirm that nivolumab was superior to ipilimumab with a HR of RFS of 0.72 (95% CI; 0.60–0.85) and DMFS HR 0.79 (95% CI: 0.63–0.99) [97]. OS results showed a non-significant benefit for nivolumab HR 0.86 (95% CI: 0.66–1.12). OS will likely have been impacted by second-line therapies, and it is important to remember that ipilimumab was an active comparator. In addition, this study included patients with resected stage IV disease. As for the safety, grade 3 or 4 adverse events (AE) were reported in 14.4% of the patients in the nivolumab arm compared to 45.9% of those in the ipilimumab group. Serious adverse events (SAE) of any grade were reported in 17.5% of the patients treated with nivolumab group and in 40.4% of patients receiving ipilimumab.

Pembrolizumab: Pembrolizumab 200 mg every three weeks for one year was tested against placebo in EORTC1325/KEYNOTE 054 trial [98] in patients with stage IIIA (>1 mm)/B/C (AJCC 7th edition) [95]. With a median follow-up of 3.5 years, RFS was significantly improved with a HR of 0.59, and an RFS rate difference at 36 months of 20% [99]. Distant metastases survival was also improved with a HR of 0.60 and differed by 16.7% at 36 months [100]. This trial did have a crossover

Table 1

Key parameters of adjuvant trials with immune checkpoint inhibitors or BRAF/MEK inhibitors that led to approvals.

Trial	Treatment arm	Comparator arm	Patient population ^a	HR for RFS/DFS	HR for OS	Grade 3–4 AEs in % ^b	Reference
EORTC 18,071 ^c CheckMate 029	Ipilimumab 10 mg/kg	Placebo	IIIA (>1 mm)/B/C	0.76	0.72	54	[75,78]
CheckMate 238	Nivolumab 3 mg/kg	Ipilimumab 10 mg/kg	IIIB/C-IV	0.72	0.86	25.4	[76]
EORTC 1325 KEYNOTE 054	Pembrolizumab 200 mg	Placebo	IIIA (>1 mm)/B/C	0.57	NA	31.6	[99]
COMBI AD	Dabrafenib 150 mg BID & Trametinib 2 mg OD	Placebo	IIIA (>1 mm)/B/C	0.51	0.57	41	[77,106]

[†] result not statistically significant.

^a Patients after complete resection of metastases, all trials used AJCC 7th edition.

^b Any AEs regardless of treatment relation.

^c Approved only by the FDA.

design allowing patients who progressed in the placebo arm to receive pembrolizumab either as adjuvant therapy following a second round of surgery or in the unresectable metastatic setting. Of 298 patients who relapsed in the placebo arm, 155 received pembrolizumab within the study protocol, 50 with resected stage III disease, and 105 with unresectable stage III/IV disease. The overall response rate (ORR) in inoperable stage IV was 38.8% and 32% of these patients were free from progression at 36 months of follow-up with no significant difference between resected and unresectable metastatic patients, just showing an expected PFS rate to anti-PD-1 in those who never received it [101]. The real measure of this crossover would be a comparison of the OS in those who were treated early in adjuvant compared to those treated later at relapse. Regarding safety, AEs of any grade were reported in 77.8% of the patients receiving pembrolizumab and in 66.1% of the patient's receiving placebo. Grade 3, 4, or 5 AE occurred in 14.7% of the patients in the pembrolizumab arm and in 3.4% in the placebo arm, with one death in the pembrolizumab arm due to myositis.

Ipilimumab and Nivolumab: CheckMate 915 trial tested a combination of nivolumab at 240 mg every two weeks and ipilimumab at 1 mg/kg every six weeks for one year against nivolumab 480 mg every four weeks in 1844 patients with completely resected stage IIIB, C, and IV melanoma. This study failed to demonstrate a significant difference in its dual endpoints of RFS in the ITT population and in patients with a tumor PD-L1 < 1%, respectively [102]. The combination therapy was associated with more toxicity than nivolumab alone. The rates of grade 3 or 4 AE were 33% with the combination vs. 13% with nivolumab; 19% of the patients in the combination arm discontinued therapy due to AE compared to 6% in the nivolumab arm. Four treatment-related deaths were reported with nivolumab plus ipilimumab and none with nivolumab alone.

In the phase II study ImmuneNED, 167 patients with stage IV melanoma without evidence of disease following surgery or radiotherapy were randomized to receive one year of either ipilimumab 3 mg/kg plus nivolumab 1 mg/kg for four doses every three weeks followed by nivolumab 3 mg/kg every two weeks; nivolumab 3 mg/kg every two weeks; or placebo. Although the median time on treatment was only 6.5 weeks in the ipilimumab and nivolumab arm, with treatment discontinuation being mostly due to high-grade toxicity, RFS after 24 months was 70% for nivolumab plus ipilimumab, compared to 42% for nivolumab and 14% for placebo, resulting in a HR of 0.23 for nivolumab plus ipilimumab over placebo [80]. In the nivolumab plus ipilimumab arm, 71% of patients experienced treatment-related grade 3–4 AEs compared to 27% in the nivolumab arm; 62% of the patients discontinued treatment due to AE in the combination arm, compared to 13% in the nivolumab arm and there were

no treatment-related deaths. Based on these results, adjuvant nivolumab plus ipilimumab can be offered to selected high-risk patients with stage IV NED melanoma following complete resection or radiotherapy, although toxicity is a major consideration.

3.4. Adjuvant-targeted therapy with BRAF/MEK inhibitors

Two large-sized, prospectively randomized trials on either the BRAF inhibitor vemurafenib alone (BRIM8) or the combination of the BRAF inhibitor dabrafenib and the MEK inhibitor trametinib (COMBI-AD) have been performed in patients with completely resected BRAF V600 mutated melanoma with locoregionally metastases (see also Table 1).

Vemurafenib: BRIM8 [103] was a trial designed before combined treatment with BRAF and MEK inhibitors became the standard of care for BRAF mutated melanoma. It compared one year of treatment with vemurafenib 960 mg BID vs. placebo in patients with completely resected BRAF V600 mutated melanoma in stages IIC, IIIA/B (cohort I), and IIIC (cohort II, all AJCC 7th edition) [95]. This study did not reach its primary endpoint as defined by the statistical plan, although it seemed to show improvement for cohort I.

Dabrafenib plus trametinib: The COMBI-AD trial [77] compared one year of the combination of 150 mg dabrafenib BID with 2 mg trametinib OD (D + T) against a matched placebo in patients with stage IIIA (>1 mm)/B/C melanoma with a BRAF-V600 E/K mutation. It demonstrated a highly significant benefit in RFS with a HR of 0.51 at five-year and a RFS rate difference of 16% [104]. An early assessment of OS differences at a median follow-up of 2.8 years did demonstrate an improvement in OS for D + T with a HR of 0.57 and a 13% difference in OS rates at three years, considered not significant. This is so far the only adjuvant study with published data on the improvement of OS.

The D + T combination was associated with pyrexia grade 1–2 in 97% with chills in 37% and grade 3–4 pyrexia in 5%. Grade 3–4 events occurred in 41% of the patients, i.e., hypertension (6%), fatigue (4%), and hepatitis (4%). Drug-related AEs lead to drug discontinuation in 26% of patients. There were no drug-related deaths. The high rate of pyrexia associated with D + T can be reduced by using the management algorithm investigated in the COMBI-Aplus trial. In this trial, D + T was interrupted promptly at the onset of pyrexia (temperature ≥ 38 °C), and if suspected recurrent pyrexia, D + T could be interrupted in the presence of pyrexia syndrome (i.e., chills, rigors, night sweats, or influenza-like symptoms without temperature ≥ 38 °C), at investigators' discretion. The trial met its primary endpoint of reducing grade 3/4 pyrexia, pyrexia-related

hospitalization, and treatment discontinuation, apparently without compromising therapy efficacy [105].

3.5. Current approval status

The clinical trials mentioned above recruited only high-risk patients in stage III, meaning that patients with stage IIIA melanoma could only be included if the metastasis in the SLNB had more than 1 mm. However, adjuvant therapies are approved in all stage III sub-stages.

3.6. Adjuvant therapy in stage II disease

Pembrolizumab 200 mg for one year was compared against placebo in more than 900 patients with stage IIB and IIC melanoma in KEYNOTE 716 trial [79]. With a median follow-up of 20.5 months, RFS did show a significant improvement with an HR of 0.61 and 86 vs. 77% of patients being free of relapse in the pembrolizumab and placebo arms at 18 months, respectively. Subgroup analyses so far show the highest benefit with an HR of 0.4 in patients with T3b melanoma. In patients with stage IIC melanoma, an HR of 0.82 was reported. These early data resulted in the approval of adjuvant pembrolizumab in stage II by the FDA, and EMA approval is expected in the near future. Regarding safety, grade ≥ 3 drug-related AEs occurred in 16.1% of the patients receiving pembrolizumab compared to 4.3% receiving placebo. Treatment discontinuation associated with AE was seen in 15.3% and 2.5% of the patients, respectively. Immune-mediated AEs, mostly grade 1 and 2, occurred in 36.2% of the patients in the pembrolizumab arm compared to 8.4% in the placebo arm. The most commonly reported immune-mediated AE were hypothyroidism (15.7% vs. 3.5%) and hyperthyroidism (10.4% vs. 0.6%).

A phase III study evaluating the role of 12 months of nivolumab in stage IIB and IIC vs. placebo (CheckMate 76 K, NCT04099251) has completed accrual, and another one that will test the use of BRAF/MEK inhibitors (COLUMBUS-AD-EORTC 1902) is shortly to open.

3.7. Future directions

Presently, there are two main directions. One is trying to increase the efficiency and toxicity/efficacy ratio of adjuvant therapies. Current adjuvant studies in completely resected stage III disease test combinations of nivolumab and the LAG3-antibody relatlimab (Relativity 098, NCT05002569) or nivolumab and the pegylated IL-2 molecule bempegaldesleukin (Pivot 12, NCT04410445) vs. anti-PD-1 monotherapy.

The other direction is to better select the candidates for adjuvant therapy. Using AJCC as a criterion of entry for adjuvant therapy results in two important

limitations: (1) a number of so-called high-risk patients with stage III, or IIB-C disease are exposed to a treatment, although they do not require it and (2) AJCC low-risk stage I and IIA account for most of the deaths in the end, because of their very high number. The challenge is thus to find the patients who will relapse whatever their AJCC group, using other biomarkers. The ongoing NivoMela trial (NCT04309409) includes patients with resected stage IIA-C and uses a prognostic gene expression signature to limit treatment to a subgroup of patients that is at a higher risk of relapse. Only patients with a positive gene expression score are randomized to treatment with either 12 months of nivolumab or observation, while patients with a negative score are only under clinical observation. Furthermore, the DETECTION Study (NCT04901988) is following 1050 patients with resected stage IIB/IIC melanoma with regular ctDNA assessment. Patients positive for ctDNA are randomized to either continue (blinded) clinical follow-up and standard of care treatment if they develop metastatic disease, or (unblinded) treatment at the time of molecular recurrence with single-agent nivolumab. This study addresses whether recurrence can be detected earlier with ctDNA monitoring than with standard clinical follow-up, and whether early treatment of molecular recurrence with immunotherapy results in a survival benefit. Finally, the EORTC 2139 – COLUMBUS AD trials is examining a year of adjuvant encorafenib + binimetinib vs. placebo for stage IIB/C melanoma.

Recommendation 21

Adjuvant therapy in stage III/IV	Evidence-based recommendation
Level of recommendation A	Adjuvant therapy (anti-PD-1 or targeted therapy) shall be offered to all patients in resected stages IIIA – IIID. Adjuvant anti-PD-1 therapy shall be offered to patients in resected stages IIIA - IIID irrespective of the mutational status. Adjuvant BRAF/MEK inhibitor therapy shall be offered to patients with BRAFV600 E/K mutation in resected stages IIIA – IIID. For fully resected stage IV melanoma patients, nivolumab can be offered regardless of mutation status.
Level of evidence: 1 b	De novo literature research [76,77,98] Consensus rate: 100%

Recommendation 22

Adjuvant therapy in stage III/IV	Evidence-based recommendation
Level of recommendation B	For stage IIIA with nodal metastasis of less than 1 mm in diameter, the uncertainty of the individual risk/benefit ratio should be carefully discussed with the patients.
Level of evidence: 1 b	De novo literature research [76,77,98] Consensus rate: 100%

4. Neoadjuvant therapy

Patients with resectable metastases, particularly clinical stage III melanoma (lymph node macro-metastases and/or skin metastasis) can be candidates for receiving a medical treatment before surgery. They might benefit from a neoadjuvant approach in different ways. The goal of neoadjuvant treatment could be firstly to limit the aggressiveness of the surgery if lesions are shrinking by the given treatment. Secondly, a personalization of adjuvant treatment management based on the assessment of the neoadjuvant therapy response might be feasible. Thirdly and ideally, a neoadjuvant treatment could lead to a complete response confirmed by histopathology and therefore major surgery might not be mandatory at all. Besides these potential benefits for the patient, a neoadjuvant treatment is the perfect setting for testing new drugs with the ability of investigating tissue biomarkers at baseline, and after investigational treatments when tumor is resected.

Since melanoma is a disease with frequent skin and lymph node metastases, it is a prototype for a rational drug development based on neoadjuvant treatment results.

A pooled analysis from the International Neoadjuvant Melanoma Consortium (INMC) [107] evaluated six available clinical trials on either anti-PD-1-based immunotherapies (PD-1-antibodies alone or ipilimumab plus nivolumab) and BRAF/MEK inhibitors. A total of 192 patients were included, of whom 141 received immunotherapies. The vast majority of patients ($n = 104$) were treated with the combination of ipilimumab (1 mg/kg) and nivolumab (3 mg/kg). The approved dose of 1 mg/kg nivolumab plus 3 mg/kg of ipilimumab was previously evaluated in the OpACIN-neo trial [108]. However, this dose showed to have a higher toxicity compared to the reduced dose of ipilimumab, without added efficacy. Therefore, the lower dose of ipilimumab was chosen for future trials. In the pooled analysis, a pathological complete response (pCR) occurred in 40% of all patients: 47% with BRAF/MEK inhibitors and 33% with immunotherapies. However, the combined immune checkpoint inhibition demonstrated a response rate of 43% in contrast to only 20% response rate in the monotherapy of anti-PD-1-antibodies. The pCR rate correlated with the improved RFS (pCR two-year: 89% vs. no pCR 50%, $p < 0.001$) and OS (pCR two-year OS 95% vs. no pCR 83%, $p = 0.027$). Very few relapses have been observed in patients with pCR, near pCR, or partial pathologically confirmed responses with immunotherapies. The two-year RFS rate for those patients was 96%. In contrast, the two-year RFS for the targeted agents was only 79% and the OS 91% [109]. A small pilot study on the LAG-3 antibody relatlimab in combination with nivolumab for patients with AJCC stage IIIB/IIIC and D and stage IV

M1a (fully resected) used only two infusions four weeks apart. The pathologically confirmed complete response rate after eight weeks in 30 melanoma patients was 52%, another 7% had an almost pCR, and 7% a pPR. However, in this particular clinical trial, all patients received a postoperative adjuvant treatment for ten months with relatlimab and nivolumab additionally. Therefore, the long-term trial results need to be considered as a combination of neoadjuvant plus adjuvant treatment. After 16 months of follow-up, 93% of the patients remained disease-free and 95% of the patients were still alive. If there was a pCR or near pCR, the RFS rate was 100%. The neoadjuvant proportion of the treatment was excellently tolerated with no grade 3/4 toxicities after eight weeks. However, in the adjuvant phase of the trial, 26% grade 3/4 toxicities were reported. There were no new safety signals.

To summarize, a number of small neoadjuvant trials have consistently shown that the neoadjuvant approach is working. Additionally, it was demonstrated that immunotherapy works better than targeted therapy, which gives high response rates, but with a lower durability. Furthermore, it was observed that combination of nivolumab plus ipilimumab is better than monotherapy with anti-PD-1 single agent, and that initial pathological response is highly predictive of RFS.

4.1. The future of neoadjuvant therapy

There are a number of other neoadjuvant trials underway. One direction is to use intralesional immune drugs since they are particularly adapted to the management of accessible tumors. This is the case of T-VEC or L910-IL2; Daromun. Another direction is to improve efficacy and toxicity/efficacy ratio of current neoadjuvant therapy, using combinations of anti-PD-1 and anti-LAG 3, for instance. A final direction is to collect information to design integrated strategies to best combine the neoadjuvant, adjuvant, and surgical approaches of the regional disease. In this regard, several trials are ongoing or planned comparing the efficacy of neoadjuvant therapy to adjuvant therapy and the combination of the two, or assessing the possibility to condition the surgery or the adjuvant treatment to the initial response to neoadjuvant treatment.

Neoadjuvant treatments are not yet a standard of care because there is a lack of prospective randomized clinical trials to demonstrate a superiority of neoadjuvant approaches over conventional surgery plus postoperative adjuvant treatment. However, with a careful discussion in tumor boards, some patients may already benefit of a treatment that is no more than a medical treatment of a regional disease. Currently, there are two neoadjuvant trials ongoing. The phase III Nadina trial (NCT04949113) is comparing routine TLND followed by routine anti-PD-1 adjuvant therapy

with two courses of neoadjuvant combination of nivolumab plus ipilimumab, followed by surgery. Another ongoing trial is the phase II SWOG 1801 study, examining routine TLND followed by adjuvant pembrolizumab (maximum of 18 courses) to neoadjuvant pembrolizumab (three courses), followed by TLND and subsequent adjuvant pembrolizumab (15 courses).

5. Systemic therapy for metastatic disease

In the last decade, the increased knowledge about signaling pathways associated with tumor development and progression, and the molecular mechanisms of signaling and controlling of the immune system transformed the survival outcomes of melanoma patients [110,111]. Indeed, these advances were responsible for increasing the RFS, DMFS, PFS, and OS in advanced melanoma patients in the last decade [112]. Despite all these advances, many stage IV patients do not benefit from these systemic therapies and died from the disease [113]. Inclusion in clinical trials is an important therapeutic option and should be offered to all eligible patients.

5.1. Immune checkpoint inhibitors

5.1.1. Monotherapy with anti-CTLA-4 and anti-PD-1

Blockade of immune checkpoint mechanisms with antibodies to CTLA-4 and PD-1 expressed by lymphocytes abrogates down-regulation of immune responses and leads to continued activation of lymphocytes, enabling killing of tumor cells. This immunostimulation is non-specific and can lead to immunologically mediated toxicity. The anti-CTLA-4 antibody ipilimumab was the first immunotherapy that showed an OS benefit in two controlled trials in metastatic melanoma [111,114–120]. Ipilimumab is approved for the treatment of stage IV melanoma both by the FDA and EMA. It is presently administered as four intravenous infusions at a dose of 3 mg/kg/infusion separated by three weeks. Serious immune-related AE, including skin rashes, colitis, thyroiditis, hepatitis, hypophysitis, and others can develop in some patients and require interdisciplinary management. Early recognition of these side effects is essential and requires specific training of the treating physicians [121,122].

The response rate to ipilimumab is only about 15%, but remarkable durable remissions were observed in stage IV patients previously treated with other drugs [123]. Patients with stable disease or initial disease progression can also benefit from prolonged survival. Meanwhile, the introduction of PD-1 antibodies changed the role of ipilimumab, which is no longer considered as the treatment of choice for first-line therapy. Currently, ipilimumab is used in combination with PD-1 antibodies or as second-line therapy.

The anti-PD-1 antibodies nivolumab and pembrolizumab are approved by both FDA and EMA for the treatment of unresectable melanoma. Nivolumab was shown to improve PFS and OS as compared to dacarbazine (CheckMate-066 trial [124]) and as compared to ipilimumab (CheckMate-067 trial [125]). Pembrolizumab showed improved PFS and OS in comparison with ipilimumab (KEYNOTE-006 trial [187]). Objective response rates of 35%–42% were achieved with PD-1 blockade. Long-term survival data after five years are available and show a survival rate of 34% for any-line treatment (KEYNOTE-001 trial) and 43% for treatment-naïve patients (KEYNOTE-006) [126,187]. During the Society for Melanoma Research (SMR) 2021 Congress, an update of the KEYNOTE-066 trial with seven-year follow-up showed that the median OS for pembrolizumab and ipilimumab was 32.7 and 15.9 months (HR = 0.70; 95% CI, 0.58–0.83) and the seven-year OS rates were 37.8% and 25.3%, respectively. This exploratory analysis showed that pembrolizumab was associated with improved clinical outcomes regardless of BRAF status, prior BRAF/MEK inhibitors therapy, high LDH level, larger tumor size, or presence of brain metastases.

PD-1 blockade is considered an effective option for the first-line treatment of patients with both BRAF wild-type and BRAF mutated tumors. The dose of nivolumab and pembrolizumab depends on which type of administration schema is used (Table 2). Both a body surface-based dose or a flat dose can be offered. The difference between these options is the frequency of the therapy, and patients' preferences and potential previous toxicities should be taken into consideration when discussing which schedule to choose [127–130].

5.1.2. Anti-PD-1 plus anti-CTLA-4

The combination of nivolumab with ipilimumab has shown to be superior, in terms of PFS, to ipilimumab and to nivolumab as single drugs (CheckMate-067 trial [125]) and is therefore approved by FDA and EMA. OS data showed a trend, but no significance in comparison with nivolumab monotherapy with the combination only. The long-term survival data after 4, 5, and 6.5 years indicate the excellent therapeutic potential with a durable, sustained survival benefit and a hope for cure, both with nivolumab alone and the combination approach [125,131,132]. Because there is substantially more toxicity, including irreversible AEs, with the nivolumab plus ipilimumab combination this treatment needs to be supervised by experienced physicians, who are familiar with irAE management procedures.

CheckMate 511 evaluated the difference in toxicity between ipilimumab 3 mg/kg plus nivolumab 1 mg/kg vs. ipilimumab 1 mg/kg plus nivolumab of 3 mg/kg for four cycles followed by nivolumab 480 mg every 4weeks [133,134]. The grade 3/4 toxicity was reduced by half, while the efficacy was largely the same in both

Table 2

Checkpoint blockade therapies for advanced cutaneous melanoma described in prospective randomized trials.

Substance	Dose	Response rate	Overall survival
Ipilimumab [111,120,123]	3 mg/kg i.v. every three weeks for four cycles	12–19%	3 y OS 22%
Nivolumab [124,137]	3 mg/kg i.v. every two weeks until tumor progression	40%–44%	
Nivolumab [127]	480 mg i.v. every four weeks (flat dose) until tumor progression		
Pembrolizumab [138] + update KEYNOTE 006 SMR 21 (ref)	2 mg/kg i.v. every three weeks until tumor progression	33%	7 y OS 37.8%
Pembrolizumab [128–130]	400 mg i.v. every six weeks (flat dose) until tumor progression		
Nivolumab + Ipilimumab [125,139]	200 mg i.v. every three weeks (flat dose) until tumor progression Ipilimumab 3 mg/kg i.v. plus nivolumab 1 mg/kg i.v. every three weeks for four cycles, continuation with 3 mg/kg nivolumab every two weeks until tumor progression	49%	6.5 y OS 49%
Nivolumab + Ipilimumab [133,135]	Ipilimumab 1 mg/kg i.v. plus nivolumab 3 mg/kg i.v. every three weeks for four cycles, continuation with 3 mg/kg nivolumab every two weeks until tumor progression	59%	3 y OS 59%
Pembrolizumab + ipilimumab (KEYNOTE 029) (ref)	Pembrolizumab 2 mg/kg every three weeks for 24 months plus four doses ipilimumab 1 mg/kg every three weeks (part 1 B)	65.8%	5 y OS 68.3%
	Pembrolizumab 200 mg every three weeks for 24 months plus four doses ipilimumab 50 mg every six weeks (part 1C arm A)	69.9%	3 y OS 74.3%
	Pembrolizumab 200 mg every three weeks for 24 months plus four doses ipilimumab 100 mg every 12 weeks (part 1C arm B)	76.7%	3 y OS 70.4%

regimens. The updated data with a median follow-up of more than 40 months show that ipilimumab 1 mg/kg plus nivolumab 3 mg/kg continue to demonstrate an improved safety profile compared with ipilimumab 3 mg/kg plus nivolumab 1 mg/kg. In the descriptive analyses, both groups demonstrated high and similar 3-year OS rates [135]. Based on these data, many centers European centers have adopted this practice.

Finally, the KEYNOTE-029 trial investigated the combination of the standard dose of pembrolizumab with an alternate dose of ipilimumab in patients with advanced melanoma [81]. In part 1 B, patients with or without previous systemic therapies received pembrolizumab 3 mg/kg every three weeks for 24 months and four doses of ipilimumab 1 mg/kg every three weeks. In part 1C, therapy naïve patients were randomized to receive pembrolizumab 200 mg every three weeks for 24 months and four doses of ipilimumab 50 mg every six weeks (arm A) or pembrolizumab 200 mg every three weeks for 24 months and four doses of ipilimumab 100 mg every 12 weeks (arm B). The last update of this trial showed that the five-year OS rate was 68.3% for part 1 B, and the duration of response for more than 48 months was 86.2%. For part C, the three-year OS was 74.3% in arm A and 70.4% in arm B, and the duration of response for more than 36 months was 82.3% and 78.7%, respectively. In terms of safety, combination therapy was well tolerated, but ipilimumab 50 mg every six weeks led to fewer grade 3–5 treatment-related AE than the regimen of ipilimumab 100 mg every 12 weeks. In part 1C, one patient in arm A died of treatment-related autoimmune myocarditis.

Presently, there are no predictive biomarkers for PD-1-based immunotherapy. The assessment of PD-L1 expression as a predictive factor was investigated in the CheckMate 067 trial [136]. Currently, available data did not show

significant differences in OS according to PD-L1 expression. Therefore, PD-L1 expression determination should not be mandatory and should not be considered for therapeutic decisions in stage IV melanoma.

5.2. Targeted therapy

In melanoma, different activating mutations have been described, mainly resulting in an increased signaling of the MAP kinase and AKT pathways [115]. About 45% of patients with cutaneous melanoma carry an activating *BRAF* V600 mutation, for which several highly selective inhibitors have been developed. Vemurafenib and dabrafenib were shown to achieve a high rapid tumor response rate (roughly 50%) in patients carrying the BRAFV600E mutation and a substantial prolongation of PFS and OS in comparison with dacarbazine (DTIC) [110,111,115,116]. Vemurafenib and dabrafenib are approved for melanoma therapy in the USA and the EU. Systemic (arthralgia and fatigue) and cutaneous AEs have been reported, including photosensitivity (only vemurafenib), development of epithelial tumors, and in rare cases new primary melanomas. Development of secondary resistance to BRAF inhibitors with varying time courses is a frequent event. MEK inhibitors supplement the inhibition of the MAP kinase pathway. Combinations of BRAF and MEK inhibitors like vemurafenib/cobimetinib (coBRIM trial [140]), dabrafenib/trametinib (COMBI-d, COMBI-v [141,142]), and encorafenib/binimetinib (COLUMBUS [143,144]) were able to show a significantly increased objective response rate, PFS, and OS in four independent phase III trials (Table 3). A pooled analysis of COMBI-d/v reported that the five-year OS rate was 34% for patients treated with dabrafenib plus trametinib. In patients with normal LDH levels at baseline, this increased to 41%. The

Table 3

Targeted therapy for advanced cutaneous melanoma described in prospective randomized trials or phase II studies, if phase III trials were not available.

Substance	Dose	Response rate	Overall survival
BRAF mutation			
Dabrafenib + Trametinib [149,150]	2 × 150 mg p.o. daily 1 × 2 mg p.o. daily	64%–67%	5 y OS 34%
Vemurafenib + Cobimetinib [140,151,152]	2 × 960 mg p.o. daily 1 × 60 mg p.o. daily for 21 days, followed by 7 days off treatment	54–68%	5 y OS 30.8%
Encorafenib + Binimetinib [143,144,153]	1 × 450 mg p.o. daily 2 × 45 mg p.o. daily	68–76%	5 y OS 34.7%
cKIT mutation			
Imatinib mesylate [147]	1 × 400 mg p.o. daily until tumor progression	23%	
NRAS mutation			
Binimetinib [148,154]	2 × 45 mg (3 × 15 mg tablets) p.o. daily until tumor progression	15%	

median OS for the combination was 25.1 months in the COMBI-d study and 26.1 months in the COMBI-v study, and the median PFS was 11.1 and 11.4 months, respectively [141]. Currently, the five-year OS data are also available for the co-BRIM and COLUMBUS study.

In the co-BRIM study, and after a median follow-up of 21.2 months for the cobimetinib plus vemurafenib arm and 16.6 months for the vemurafenib arm, the median OS was 22.5 months and 17.4 months, respectively (95% CI: 20.3–28.8 and 15.0–19.8). The 5-year OS rates were 31% for the combination therapy and 26% for the monotherapy. As for the median PFS, it was 12.6 months for patients receiving cobimetinib plus vemurafenib and 7.2 months for patients receiving vemurafenib (95% CI: 9.5–14.8 and 5.6–7.5). The five-year PFS rates were 14% and 10%, respectively. Also in this study, the OS and PFS were longer in patients with normal baseline LDH levels and low tumor burden, but also in those with complete response [145].

In the COLUMBUS study and for patients receiving encorafenib plus binimetinib, the median OS and five-year OS rate were 33.6 months and 34.7%, respectively (95%CI: 24.4–39.2 months and 28.0–41.5%). The five-year PFS rate was 22.9% with a median duration of response of 18.6 months. For patients with normal baseline LDH levels, the five-year OS rate was 45.1% (95%CI: 36.5–53.2). Patients receiving encorafenib 300 mg QD and vemurafenib monotherapy had worse survival outcomes and shorter median duration of response [146].

A small proportion of melanomas arising in sun-protected sites have mutations in cKIT and they have been treated with the cKIT inhibitor imatinib-mesylate. Responses have been described in case reports and a phase II trial showed an objective response rate of 23% in patients with cKIT mutated melanoma (Table 3) [147]. There is significant variability in response rate and response duration. This is probably due to the significant number of different c-Kit mutations and the lack of consistency of response even when the same mutation is present.

An NRAS mutation is detected in 15–20% of cutaneous melanomas. Presently, there are no effective NRAS-inhibiting molecules available. Trials have been performed investigating MEK inhibitors like binimetinib (NEMO trial [148]) and pimasertib (NCT01693068) in this setting. A low response rate has been observed with no significant impact on OS. Furthermore, the MEK inhibitor binimetinib appeared to be more toxic than a single-agent treatment with conventional DTIC chemotherapy [148].

5.3. Therapy sequence in BRAF mutated melanoma

Patients with BRAF mutated tumors may be offered therapy with PD-1-based immunotherapy or BRAF/MEK inhibitors. An indirect comparison of 26 trials representative of these two treatment strategies in advanced metastatic melanoma was published by Ugurel et al in 2020 [155]. In first-line setting, the averaged three-year OS proportions were 58.4% for CTLA-4 plus anti-PD-1, 49.9% for anti-PD-1, and 41.3% for BRAF/MEK. For second line or later, combined BRAF/MEK was superior to PD-1 monotherapy in the first three years; averaged three-year OS proportions were 42.4% for BRAF/MEK, and 40.1% for PD-1 inhibitors.

In order to prospectively answer the question, the phase II SECOMBIT trial, investigated three different therapeutic approaches in this subgroup of patients, using combined targeted therapy with encorafenib plus binimetinib and nivolumab plus ipilimumab. In arm A, patients received encorafenib plus binimetinib until progression followed by combined immunotherapy; in arm B, patients received combined immunotherapy first until progressive disease, followed by combined targeted therapy; in arm C, patients received encorafenib plus binimetinib for eight weeks, followed by combined immunotherapy until progression, followed by combined targeted therapy. The last update with a median follow-up of 32.2 months was presented in the ESMO21 congress. The mOS was not reached in either arm. The three-year OS rate was 54%, 62%, and 60% in arms A,

B, and C, respectively, and the three-year PFS rate was 41%, 53%, and 54% in arms A, B, and C, respectively [156].

The phase III DREAMSeq trial also investigated the best sequence in patients with BRAFV600 mutated melanoma [157]. Therapy naïve stage IV melanoma patients with BRAFV600 mutation were randomized 1:1 to receive either nivolumab plus ipilimumab (arm A) or dabrafenib plus trametinib (arm B) until disease progression. In this case, patients were then enrolled into the second phase of the study to receive the alternate therapy – combined targeted therapy (arm C) or combined immunotherapy (arm D).

Long-term OS was higher in patients receiving combined immunotherapy (arm A) followed by targeted therapy (arm C) than in the reverse sequence. The two-year OS rate for patients starting in arm A was 72% and 52% for those starting with arm B. Increased OS was seen after ten months, indicating the importance of switching to targeted therapy salvage in the small percentage of patients with rapid progression on first-line immunotherapy.

5.4. *Talimogene laherperepvec*

T-VEC is an oncolytic viral therapy approved for the local treatment of unresectable metastatic stage IIIB/C–IVM1a melanoma.

The MASTERKEY-265 is a phase III randomized trial that investigated the treatment with pembrolizumab with or without T-VEC in unresectable, treatment naïve stage IIIB/IVM1c melanoma patients. Patients with BRAF mutated melanoma previously treated with one BRAF/MEK combination were also included. Patients were randomized 1:1 to receive T-VEC plus pembrolizumab or placebo plus pembrolizumab, and the primary endpoint was PFS by blinded independent central review or OS. The final results were presented showing that the mPFS for T-VEC plus pembrolizumab and pembrolizumab alone was 14.3 months and 8.5 months, respectively (95%CI: 10.25–22.11 and 5.72–13.54; HR 0.86 (95% CI 0.71, 1.04), $P = 0.13$). The mOS was not reached in the combination arm and was 49.2 months in the pembrolizumab arm (40.57–NR; HR 0.96 (95% CI 0.76, 1.22), $P = 0.74$). No new safety issues were reported. In conclusion, the addition of T-VEC to pembrolizumab did not improve PFS or OS compared to pembrolizumab alone [158].

Currently, it is unclear what is the place for the combined therapy of T-VEC and anti-PD-1. However, based on the data OPTiM trial, T-VEC can continue to be offered to patients with unresectable stage IIIB–IVM1c melanoma [159].

5.4.1. *Anti-LAG3*

The RELATIVITY-047 trial is a phase III trial that investigates the first-line relatlimab plus nivolumab vs.

nivolumab alone in patients with advanced melanoma [160]. Lymphocyte-activation gene 3 (LAG 3) is an immune checkpoint that inhibits T-cell activity and is upregulated in several tumor types, including melanoma. Relatlimab is a human anti-LAG-3 that restores the effector function of exhausted T-cells. In this trial, patients were randomized to receive a fixed-dose combination of relatlimab 160 mg plus nivolumab 480 mg every four weeks (RELA + NIVO FDC) or nivolumab monotherapy, until progression or unacceptable toxicity. The primary endpoint was PFS by blinded independent central review, and the secondary endpoints were OS and ORR. The first results showed that the median PFS was 10.1 months in the RELA + NIVO FDC group (95% CI: 6.4–15.7) and 4.6 months in the monotherapy group (95% CI: 3.4–5.6; HR 0.75; 95% CI, 0.6–0.9; $p = 0.0055$). The incidence of grade 3 or 4 treatment-related AE was higher in the combination arm (18.9% vs. 9.7%).

An exploratory analysis was later presented showing the potential benefit in terms of subgroups and beyond initial treatment [161]. Data on PFS 2 – time from randomization to progression after the next line of systemic therapy, per investigator assessment, or death – were also presented. The median PFS2 was not reached for RELA + NIVO FDC (95% CI 21.8–NA) and was 20 months in the nivolumab arm (95%CI: 15.4–25.1); HR 0.77 (95% CI 0.61–0.97). Finally, patients treated with RELA + NIVO FDC had a longer treatment-free interval compared to those receiving nivolumab monotherapy, i.e., 3.98 months vs. 1.45 months (95%CI: 2.10–7.43 and 1.25–171, respectively; HR 0.63; 95%CI 0.48–0.83).

With these data, two questions arise:

- (1) How can we select patients to receive RELA + NIVO FDC, as the benefit for RELA + NIVO FDC was seen regardless of LAG-3 expression.
- (2) Where should we place this combination when comparing with the results of CheckMate-067, CheckMate-511, and KEYNOTE-029 trials? Here, more mature data are needed, especially OS data, before a recommendation can be given.
- (3) Is nivolumab monotherapy still standard of care? Also, when comparing (indirect comparison) the median PFS data from the nivolumab arm in the RELATIVITY-047 trial and the CheckMate-067, the results are numerically different, with patients in the nivolumab arm of the CheckMate 067 doing better than those treated in the RELATIVITY-047 trial (mPFS was 6.9 months and 4.6 months (95% CI 5.1–9.7 and 3.4–5.6, respectively).

5.5. *Chemotherapy*

Before targeted and immunotherapies became available, chemotherapy was the only systemic treatment that could be offered to stage IV melanoma patients.

Presently, chemotherapy may only be considered as last-line treatment in patients with resistance to immunotherapies and – where applicable – targeted therapies and/or if participation in a clinical trial is not available [162]. However, single-agent and combination chemotherapy may still play a role in countries where the new and more effective drugs are still not available and/or reimbursed. Finally, chemotherapy can also be considered in particular situations of patients without BRAF mutation and who developed severe toxicity to immune checkpoint inhibitors.

A number of agents with comparable effectiveness are used for systemic chemotherapy of advanced melanoma. Chemotherapy can lead to the regression of tumors and a reduction in tumor-related symptoms, but no regimen has demonstrated a survival advantage over symptom palliation. The longest-established monotherapy is DTIC. Several multicenter trials, however, have demonstrated that response rates are in the range of only 5–12% with few complete responses (Table 4) [163–166].

Table 4

Examples of monochemotherapy and polychemotherapy for advanced cutaneous melanoma described in prospective randomized trials or phase II studies, if phase III trials were not available.

Medication	Dose	Response rate
Dacarbazine [166–169]	250 mg/m ² i.v. daily for five days every three–four weeks	12.1–17.6%
	800–1200 mg/m ² i.v. daily on one day every three–four weeks	5.3–23%
Temozolomide [166,170]	150–200 mg/m ² p.o. daily for five days every four weeks	13.5–21%
Fotemustine [171,172]	100 mg/m ² i.v. on days 1, 8, and 15; then four weeks pause and then repeat single dose every three weeks	7.4–24.2%
CarboTaxol [173]	Carboplatin AUC6 i.v. day 1, after four cycles reduce to AUC4 Paclitaxel 225 mg/m ² i.v. day 1 every three weeks, after four cycles reduce to 175 mg/m ²	(12.1% second line)
DVC [174]	DTIC 450 mg/m ² i.v. days 1 + 8 Vindesine 3 mg/m ² i.v. days 1 + 8 Cisplatin 50 mg/m ² i.v. days 1 + 8 every three–four weeks	24%

Recommendation 23

Immunotherapy in stage IV	Evidence-based recommendation
Level of recommendation A	In stage IV patients, immunotherapy with checkpoint inhibitors shall be offered as first-line, irrespective of BRAF status. The options include anti-PD-1 monotherapy and combination of anti-PD-1 plus anti-CTLA-4 (in different doses and schedules). PD-L1 expression determination should not be mandatory and should not be considered for therapeutic decisions in stage IV melanoma.
Level of evidence: 1a	De novo literature research [124,130–133,135,137–139] Consensus rate: 100%

Recommendation 24

Oncolytic viral therapy in advanced melanoma	Evidence-based recommendation
Level of recommendation B:	In unresectable stage IIIB/C-IVa melanoma patients, therapy with T-VEC can be recommended.
Level of evidence: 1 b	De novo literature research [158,159]; Consensus rate: 85%

Recommendation 25

Targeted therapy in stage IV	Evidence-based recommendation
Level of recommendation B	In particular scenarios* for patients with stage IV melanoma and a BRAF-V600 E/K mutation, first-line therapy with BRAF/MEK inhibitors should be offered as an alternative to immunotherapy.
Level of evidence: 1 b	De novo literature research [140,142–146,187] Consensus rate: 100%

*Poor performance status, high LDH, high tumor burden, aggressive course of the disease, symptomatic brain metastases, and patient's preference.

Recommendation 26

Targeted therapy in stage IV	Evidence-based recommendation
Level of recommendation A	In patients with resistance to immunotherapy and harboring a BRAF-V600 E/K mutation, BRAF/MEK inhibitors shall be offered in second line.
Level of evidence: 1 b	De novo literature research [140,142–146,187] Consensus rate: 100%

Recommendation 27

Chemotherapy in stage IV	Consensus-based recommendation
GCP	Chemotherapy can be considered in patients with good PS only when there is resistance to immunotherapy and targeted therapies. The alternative is palliative best supportive care. Consensus rate: 100%

5.6. Brief conclusions on stage IV treatment

Presently, insufficient data are available to establish a comprehensive treatment algorithm for stage IV melanoma. The basic structure of decisions in the therapy of non-resectable melanoma is shown in Fig. 1. That being said some general principles can be applied:

- ◆ The treatment of metastatic melanoma patients should be discussed in interdisciplinary tumor boards with representation from multiple oncology sub-specialties.
- ◆ Mutation testing of tumor tissue (at least a search for *BRAF* mutations) is a prerequisite for treatment decisions and should be performed preferentially in metastatic tumor tissue from AJCC stage IIIB onward.
- ◆ Further targeted panel sequencing should be offered when available.
- ◆ PD-1 blockade either as monotherapy or in combination with CTLA-4 blockade should be considered for first-line treatment for all patients with unresectable metastatic melanoma and independent from tumor *BRAF* status. For selected patients, targeted therapy may be a more appropriate first-line if *BRAF* mutation is present.
- ◆ The combination of *BRAF*/*MEK* inhibitors is the standard of care for patients receiving targeted therapies. Monotherapy with *BRAF* inhibitors alone is not recommended unless *MEK* inhibitors are contraindicated.
- ◆ Chemotherapy may be considered in patients with a good performance status, who are resistant to targeted therapies and immune checkpoint modulators, or in those with *BRAF* wild-type tumors who developed severe toxicity to immunotherapy.
- ◆ *C-KIT* inhibitors may play a minor role in the second-line treatment of *CKIT*-mutant melanomas if PD-1-antibodies with or without ipilimumab have been used already.

5.7. Brain metastasis

Until 2010, systemic therapy in melanoma brain metastasis was limited to using chemotherapeutic agents (mainly fotemustine) after the failure of local therapies. However, melanoma treatment of brain metastases has seen a recent surge in novel therapeutics, including anti-PD-1 immunotherapy and targeted therapy effective in treating CNS metastases.

The current standard of care for asymptomatic brain metastases is a systemic therapy. However, ongoing trials might change the landscape of therapeutic options for these patients in the near future.

5.7.1. Immunotherapy

In the first trial of immunotherapy for patients with brain metastases, the CTLA-4 antibody ipilimumab was tested in an open-label phase II study in patients with asymptomatic and symptomatic brain metastases [175]. While an intracranial response rate of 16% and long-term benefit were seen in asymptomatic patients, the response rate deteriorated to 5% in symptomatic patients.

Immunotherapy with PD-1 blocking antibodies or in combination with CTLA-4 blocking monoclonal antibodies has been tested in two recent prospective trials – the CheckMate 204 trial and the ABC trial. The CheckMate 204 study investigated combined immunotherapy with nivolumab and ipilimumab in patients with asymptomatic (cohort A) and symptomatic (cohort B) melanoma brain metastases [176]. The last updated results from this trial were presented during the ESMO21 congress. In cohort A, the 36 months intracranial PFS rate was 52% (95%CI: 41%–65%), and the OS rate was 72% (95%CI: 62%–80%). In cohort B, the 36 months intracranial PFS rate was 28% (95CI: 10%–50%), and the OS rate was 37% (95%CI: 14%–60%) [177].

The Australian ABC trial reported similarly outstanding results for combined nivolumab and ipilimumab in asymptomatic patients not requiring steroids [64]. This study investigated immunotherapy in three different cohorts of patients. Patients with asymptomatic brain metastases with no prior local brain therapy were randomized to receive nivolumab 1 mg/kg plus ipilimumab 3 mg/kg, Q3W for four cycles followed by nivolumab 3 mg/kg Q2W (cohort A), or nivolumab 3 mg/kg Q2W (cohort B). Patients with brain metastases who failed local therapy had neurological symptoms and/or with the leptomeningeal disease were treated with nivolumab 3 mg/kg Q2W (cohort C). The last updated data presented during the ASCO21 congress showed that in cohort A, the five-year intracranial PFS rate was 46%, and the five-year OS rate was 51%. For treatment naïve patients, the five-year intracranial PFS rate was 52% with a five-year OS rate of 55% [178].

5.7.2. Targeted therapy

The BREAK-MB trial demonstrated the impact that dabrafenib had in brain metastases with a 39% and 30% intracranial response rate in patients without and following progress after previous local treatment of their brain metastases, respectively [119]. In COMBI-MB trial, the combination of dabrafenib and trametinib showed an objective response rate of 58% in patients carrying a *BRAF* V600 mutation without neurologic symptoms and a comparable response rate in a small group of symptomatic patients. The duration of response was, however, only 6.5 months in asymptomatic and 4.5 months in symptomatic patients [179]. In a general manner, the factors associated with shorter OS included male sex, cerebellar involvement, higher number of metastatic brain tumors, concurrent

Recommendation 28

Systemic therapy for brain metastases	Consensus-based recommendation
Level of recommendation A:	In eligible patients with brain metastases, combined immunotherapy shall be offered as first-line therapy.
Level of evidence: 1 b	De novo literature research [177,178]; Consensus rate: 100%

Recommendation 29

Systemic therapy for brain metastases	Consensus-based recommendation
---------------------------------------	--------------------------------

Level of recommendation C:	Targeted therapy can be an alternative in patients with BRAFV600 E/K mutation, especially in symptomatic brain disease.
----------------------------	---

Level of evidence: 1 b	De novo literature research [177,178]; Consensus rate: 100%
------------------------	--

presence of adrenal metastasis, or treatment with whole brain radiation therapy.

5.7.3. Local therapy

Melanoma often metastasizes to the brain, which is associated with a worse prognosis. Surgery is considered as potentially curative in patients with solitary or few brain metastases. Symptom control may be established in the short term with systemic corticosteroids by reducing secondary edema. SRS can likewise be potentially curative for brain metastasis [180]. There is no difference between SRS and surgical resection in terms of the local control of brain metastases. SRS was associated with improved early local control of treated lesions compared with surgical resection, although the relative benefit decreased with time [181]. Both stereotactic single-dose radiation therapy and surgical resection are appropriate for solitary or few (typically up to 5) and smaller lesions (up to 3 cm in diameter), although newer devices allow the treatment of more lesions in selected cases. Treatment of solitary lesions (surgery or stereotactic RT) can be applied several times and appears to prolong PFS, although this has never been established in randomized trials. WBRT is generally palliative, does not prolong survival, and can no longer be recommended for the treatment of melanoma brain metastases. In emergency situations, with acute neurological symptoms, surgery should be considered as the first option.

Recommendation 30

Surgery and radiotherapy for brain metastases	Evidence-based recommendation
---	-------------------------------

Level of recommendation B	Eligible patients with brain metastases should be treated with stereotactic radiotherapy. Surgery can be an option when stereotactic radiotherapy is not possible. Guideline adaptation [16,17] Consensus rate: 100%
---------------------------	--

Recommendation 31

Whole brain radiotherapy (WBRT)	Evidence-based recommendation
---------------------------------	-------------------------------

Level of recommendation C	Whole brain radiotherapy can no longer be recommended for the treatment of melanoma brain metastases. Guideline adaptation [16,17] Consensus rate: 100%
---------------------------	---

5.7.4. Combined approaches

The combination of SRS with systemic therapies (BRAF/MEK inhibition and PD-1-based immunotherapy) has been reported in numerous retrospective studies with improved intracranial control, as well as encouraging PFS and OS data [182]. Currently, definitive results from prospective trials investigating the combination of checkpoint inhibitors or BRAF/MEK inhibitors and radiotherapy/surgery are still missing, and the best sequence remains to be determined [183–185].

5.8. Progression after PD-1-based immunotherapy

Patients with BRAF wild-type melanoma, who do not respond to PD-1-based immunotherapy, particularly to combined anti-PD-1 and anti-CTLA-4, have very limited therapeutic options available. Recently, data evaluating second-line therapies in this setting have been presented. Yet, it is our opinion that inclusion in a clinical trial is still the best option available for this collective of patients.

5.8.1. PD-1 rechallenge

Patients treated with anti-PD-1 monotherapy can derive benefit from a second course of anti-PD-1, particularly when they benefited from the first-line therapy, i.e., when response at the time of discontinuation was at least SD. Data from the KEYNOTE 066 trial showed that for patients receiving second-line pembrolizumab, the mOS was 23.5 (16.8–34.2), and the five-year OS rate was 32.3 (25.5–39.3). [186] Also, in the CheckMate 067 trial, 152 patients included in the nivolumab arm received subsequently systemic therapy with another immunotherapy (n = 105), namely anti-PD-1 (n = 49) [131].

5.8.2. Ipilimumab and ipilimumab plus anti-PD-1

Ipilimumab alone or in combination with nivolumab can also be a therapeutic option for patients progressing to PD-1-based immunotherapy. In the KEYNOTE 066 trial, the mOS for second-line ipilimumab was 13.6 months (10.7–22.0), and the five-year OS rate was 27.3% (18.3–37.0).

In the CheckMate 067 trial, 91 patients in the nivolumab arm received subsequent systemic therapy with ipilimumab, but the survival benefit associated with this second line was not reported. Finally, in a multicenter retrospective analysis, it was shown that after progression under PD-1 therapy combined nivolumab plus ipilimumab resulted in a higher response rate and longer PFS and OS compared to ipilimumab monotherapy, with similar toxicity [187]. Therefore, when possible, the combination therapy should be preferred.

5.8.3. Adoptive T-cell transfer

Adoptive T-cell transfer (ATT) of tumor-infiltrating lymphocytes represents a potential alternative therapy for resistance to immune checkpoint inhibition, which is currently under development. Ex vivo-expanded tumor-infiltrating lymphocytes (TILs) are administered to lymphodepleted melanoma patients along with high-dose IL-2. High rates of clinical response and long-term survival have been reported for this therapy [188]. Currently, there are no approved TIL-ATT regimens. The process of producing TILs is technically challenging, and concomitant administration of IL-2 is associated with significant toxicity.

An open-label phase II study was conducted to determine the efficacy and safety of a TIL-ATT (lifileucel) in 66 patients with unresectable metastatic melanoma and progression on anti-PD-1 therapy or BRAF/MEK inhibition [189]. The study regimen began with a one-week nonmyeloablative lymphodepletion with 60 mg/kg cyclophosphamide and 25 mg/m² fludarabine, followed by a single infusion of lifileucel. Patients then received up to six doses of interleukin (IL)-2. The median follow-up time was 28.1 months. There was an objective response rate of 36.4%, with a complete response rate of 4.5%. Forty-four percent of patients had stable disease after treatment, for an overall disease control rate of 80.3%. An application for approval has been submitted to the FDA.

5.8.4. Lenvatinib

The phase II LEAP-004 trial evaluated the combination of lenvatinib, a multi-kinase inhibitor, and pembrolizumab in stage III/IV melanoma patients with confirmed progressive disease per iRECIST within 12 weeks of the last dose of a PD-1/L1 inhibitor given alone or with anti-CTLA-4 or other therapies for two or more doses. Results from the 103 patients included showed that this combination could be an option for this subgroup of patients [190]. After a median follow-up of 15.3 months, approximately 18% of the patients were still under therapy, with an ORR of 21.4% (95% CI: 13.9%–30.5%). The median duration of response was 8.2 months. For the subgroup of patients who have received anti-PD-1 and anti-CTLA-4, the ORR was 33%. For patients with primary resistance to immunotherapy (n = 62), the ORR was 22.6% and for those with secondary resistance (n = 22), the ORR was 22.7%. Finally, the median PFS for the whole collective was 4.2 months (95%CI: 3.8–7.1), the median OS was 14 months (95%CI: 10.8–NR), and the one-year PFS and OS estimates were 17.8% and 54.5%, respectively.

Recommendation 32

Progression after PD-1-based immunotherapy	Consensus-based recommendation
Level of recommendation B:	In patients with resistance to PD-1 monotherapy, combined immunotherapy with anti-PD-1 and anti-CTLA-4 or CTLA-4 monotherapy should be offered. In BRAFV600 mutated patients, targeted therapy shall be offered. For patients with BRAF wild-type tumors and resistance to combined anti-PD-1 and anti-CTLA-4 immunotherapy, inclusion in a clinical trial is the best therapeutic option.
Level of evidence: 2	De novo literature research [189,190]; Consensus rate: 100%

5.9. Acral melanoma

Acral melanoma is a unique subtype of melanoma occurring on the palms, soles, and nails. Its development is independent of UV exposure, and its frequency is similar in all ethnic populations. The tumor mutation burden (TMB) of acral melanoma is comparatively low and is about one power of ten lower than that of cutaneous melanoma. In a comparative study of metastatic tissue, the TMB was 9.5 mut/mB for cutaneous melanoma and 1.5 mut/mB for acral melanoma [191]. Cutaneous melanoma is induced by UV radiation and therefore carries a high number of mutations leading to an excellent response to immunotherapies. In contrast, the response of acral melanoma to immunotherapy is significantly lower. A meta-analysis of studies on the treatment of metastatic acral melanoma with checkpoint inhibitors showed an objective response rate of 20%, which is significantly higher than with chemotherapy. In acral melanoma, treatment with anti-PD-1 (n = 330) was associated with significantly better OS at 12 months (53%) than patients treated with anti-CTLA-4 therapies (n = 94) (34% survival at 12 months, P < 0.001) [192]. The combination therapy of anti-CTLA-4 and anti-PD-1 immunotherapy showed increased efficacy with an objective response rate of 43% as compared to single-agent therapy [193]. Up to 20% of acral melanomas carry a BRAF V600 mutation [194]. Therefore, in metastatic acral melanomas, mutation diagnosis should always be performed and the possibility of therapy with BRAF/MEK inhibitors should be considered as in other subtypes of melanoma. cKIT mutations occur in 5–10% of acral melanomas. Treatment with imatinib of advanced melanomas with c-KIT alterations shown some efficacy in terms of ORR – treatment with imatinib had an ORR of 23.3% and with nilotinib an ORR of 26.2% in phase II trials [195]. Treatment of metastatic

acral melanoma follows the same recommendations as for other metastatic cutaneous melanomas. In the first line, immunotherapy with PD-1 inhibitors or combined immunotherapy with PD-1 and CTLA-4 inhibitors should be offered. In the second line, BRAF/MEK inhibitors as well as cKIT inhibitors should be used if the corresponding mutations are present.

5.10. Mucosal melanoma

The following information is an abbreviated discussion on the therapeutic options for metastatic mucosal melanoma and do not replace detailed guidelines [196,197].

The CheckMate 067 trial included a small subgroup of patients with mucosal melanoma ($n = 79$) who received therapy with nivolumab plus ipilimumab or nivolumab or ipilimumab alone. With a minimum follow-up time of 60 months, the five-year ORR, PFS, and OS were higher in the subgroup of patients receiving combined immunotherapy compared to nivolumab or ipilimumab alone. The ORR was 43% for nivolumab and ipilimumab, 30% for nivolumab, and 7% for ipilimumab; PFS was 29%, 14%, and 0%, respectively; and OS was 36%, 17% and 7%, respectively. The better outcomes with nivolumab plus ipilimumab follow those seen in patients with cutaneous melanoma [131], but, globally, the survival results are less favorable [198]. Currently, inclusion in a clinical trial is still the best therapeutic option for patients with metastatic mucosal melanoma.

Recommendation 33

Systemic therapy for mucosal melanoma	Consensus-based recommendation
Level of recommendation B:	Patients with metastatic mucosal melanoma should be offered combined immunotherapy with anti-PD-1 and anti-CTLA-4
Level of evidence: 1 b	De novo literature research [198]; Consensus rate: 100%

5.11. Uveal melanoma

The following information is an abbreviated discussion on the therapeutic options for metastatic uveal melanoma and do not replace detailed guidelines [199].

Uveal melanoma is currently considered a distinct disease entity recognized by EMA and is regarded as an orphan disease. Melanomas of the eye involve the uvea, ciliary body, or the retina. They have a different pattern of metastasis than cutaneous melanomas. Since the eye does not have a lymphatic system, no lymph node metastases occur in uveal melanoma. Almost all metastases are found in the liver following hematogenous spread. For this reason, the prognosis of metastatic ocular

melanoma is in general worse than that of its cutaneous counterpart. On the other hand, when patients with liver metastases from ocular and cutaneous melanoma are compared, there are no significant differences in the disease progression.

Because of the preferential metastasis to the liver, patients with ocular melanoma and liver metastases may be candidates for local-regional therapeutic measures, such as surgery, chemoablation, chemoembolization, radiofrequency ablation, or STR.

In retrospective studies, systemic therapy with PD-1-based immunotherapy, particularly combined anti-PD-1 and anti-CTLA-4, provided survival benefit, but were lower than observed in patients with cutaneous melanoma [200]. Uveal melanoma has in general a low TMB.

Recently, a new systemic therapy has been shown to improve survival in patients with metastatic uveal melanoma. Tebentafusp is a fusion protein consisting of the T-cell receptor recognizing gp100 fused to CD3. Tebentafusp acts by bridging the tumor – that express gp100 – and the immune cells, enabling the immune cells to recognize and eliminate the melanoma cells expression gp100. The caveat of this therapy is that the T-cell receptor-binding domain only recognizes a specific gp100 peptide present on human leukocyte antigen (HLA)-A*0201, which restricts this therapy to this HLA subtype. Tebentafusp was evaluated in a phase III randomized clinical trial that compared tebentafusp with investigators' choice in first-line metastatic uveal melanoma. With a median follow-up of 14 months, the median OS was approximately 22 months in the tebentafusp arm compared to 16 months for investigator's choice arm. This represents a 49% risk reduction for disease progression or death, which is statistically significant ($p < 0.001$). The one-year OS rate was 73% for patients receiving tebentafusp compared to 59% in the investigator's choice arm. The six-month PFS rate was also superior in the tebentafusp arm (31% compared to 19%; HR for disease progression or death, 0.73; 95% CI, 0.58 to 0.94; $p = 0.01$) [201].

Another phase II trial investigating the combination of pembrolizumab and entinostat – a histone deacetylase (HDAC) inhibitor – in metastatic uveal melanoma was recently published [202]. The primary endpoint was ORR. After a median follow-up of 14.8 months, the ORR was 14% (95% CI: 3.9%–31.7%). The clinical benefit rate at 18 weeks was 28%, with a median PFS of 2.1 months and a median OS of 13.4 months. The one-year PFS rate was 17% and the one-year OS rate was 59%. Better results were seen in patients with BAP1 wild-type tumors.

5.12. Progression after adjuvant therapy

There is very limited data on the type of therapy to be offered to patients who progress with irresectable disease after adjuvant systemic therapy [203]. Patients with

primary resistance to systemic adjuvant therapy, i.e., those who progress while receiving adjuvant therapy or shortly after (less than six months) have a low likelihood of responding to a re-challenge. For patients who develop progressive disease more than six months after adjuvant therapy, re-challenge can be considered. BRAF status should be considered both in the primary and acquired resistance setting. For patients with BRAF mutated melanoma, switching from immunotherapy to targeted therapy or vice-versa can be considered. For patients with BRAF wild-type, combination therapy with anti-PD-1 plus ipilimumab or ipilimumab alone can be an option. Besides systemic therapy, for patients with limited progressive disease that can be treated with local therapy, surgical resection, radiotherapy, or a combination of both should be considered [203,204].

Currently, besides BRAF status, there are no other biomarkers than can guide therapeutic decision in this setting.

Recommendation 34

Systemic therapy for irresectable Consensus-based recommendation disease after adjuvant therapy

Level of recommendation C:	For patients with acquired resistance, re-challenge with the same type of therapy can be considered.
----------------------------	--

Level of evidence: 4	De novo literature research [203,204]: Consensus rate: 100%
----------------------	--

6. Consensus-building process and participants

These guidelines originate from contributors who were involved in the development of their national guidelines. These national guidelines were elaborated by the different specialties involved in the management of melanoma patients (dermatology, medical oncology, surgical oncology, radiotherapy, pathology, and others).

These guidelines were prepared under the auspices of the European Dermatology Forum (EDF), the European Association of Dermato-Oncology (EADO), and the European Organization for Research and Treatment of Cancer (EORTC). In a first round, medical experts who participated in their national guideline development processes were involved. In a second round, the EORTC selected experts from different specialties to contribute to these guidelines. This process was first organized in 2008/2009, and the update was developed by the same groups in 2012 and 2016. The formal recommendations were discussed and agreed upon at the consensus conference on the 26th November 2021 in Rome by the Guideline Group represented by 20 European experts. Professor Claus Garbe, from Tübingen, coordinated the activities of the selected experts and the

final authors. These guidelines are planned to be updated at least every two years.

Information about the guideline

The European Interdisciplinary Guideline on melanoma was written as a uniform text and then published in two separate but integral parts: Part 1 on diagnosis and Part 2 on treatment. Information about the guideline is detailed in Garbe et al. Part 1, including the information about societies in charge, financing of the guideline, scope, target population, objectives, methodology, audience, and period of validity. The levels of evidence were graded according to the Oxford classification (detailed in Garbe et al. Part 1). Recommendations were based on the level of best quality available evidence. The grades of recommendation were classified as follows (A) strong recommendation - syntax: “shall”. Based on good-quality evidence (B) recommendation - syntax: “should”. Based on inconsistent or limited quality evidence (C) recommendation pending - syntax: “may/can” .

Disclaimer

Medicine is subject to a continuous development process. Therefore, all statements, in particular on diagnostic and therapeutic procedures, can only correspond to the scientific knowledge current at the time of printing of this guideline. The attending physician invoking these guideline recommendations must take into account scientific progress since the publication of the guideline.

Scope

This guideline has been written in order to assist clinicians in treating patients with invasive cutaneous and metastatic melanoma. This publication was conceptualized mainly due to advances in the medical treatment of patients with cutaneous melanoma, which justify a newer multidisciplinary therapeutic strategy. The use of these guidelines in the clinical routine should improve patients' care.

Conflict of interest statement

Dr. Garbe reports personal fees from Amgen, personal fees from MSD, grants and personal fees from Novartis, grants and personal fees from NeraCare, grants and personal fees from BMS, personal fees from Philogen, grants and personal fees from Roche, grants and personal fees from Sanofi, outside the submitted work.

Dr. Amaral reports institutional grants and personal fees from Novartis, institutional grants from NeraCare, personal fees from BMS, institutional grants from Sanofi, institutional grants from SkylineDx, personal fees from CeCaVa, personal fees from Pierre Fabre, outside the submitted work.

Dr. Peris reports personal fees from Novartis, personal fees from Roche, personal fees from Sanofi, personal fees from Lilly, personal fees from Leopharma, personal fees from Pierre Fabre, personal fees from Almirall, personal fees from Celgene, outside the submitted work.

Dr. Hauschild reports grants and personal fees from Amgen, grants and personal fees from BMS, grants and personal fees from Eisai, grants and personal fees from Immunocore, grants and personal fees from MerckPfizer, grants and personal fees from MSD/Merck, grants and personal fees from Novartis Pharma, grants and personal fees from Philogen, grants and personal fees from Pierre Fabre, grants and personal fees from Regeneron, grants and personal fees from Replimune, grants and personal fees from Roche, grants and personal fees from Sanofi-Genzyme, grants and personal fees from Seagen outside the submitted work.

Dr. Arenberger reports personal fees from Amgen, personal fees from MSD, personal fees from Novartis, personal fees from BMS, grants and personal fees from Pfizer, personal fees from Sanofi, outside the submitted work.

Dr Basset-Seguin has nothing to disclose.

Dr. Bastholt reports personal fees for advisory boards from Bristol Myers-Squibb, Pierre Fabre, Merck MSD, Novartis and Roche, outside the submitted work.

Dr. Bataille has nothing to disclose.

Dr. del Marmol reports grants and personal fees from BMS, grants and personal fees from SANOFI, personal fees from Merck, grants and personal fees from almirall, personal fees from ABBVIE, personal fees from LEO pharma, personal fees from SUN Pharma, personal fees from Genzyme, outside the submitted work.

Dr. Dréno reports grants and personal fees from BMS, personal fees from MSD, grants and personal fees from Roche, grants and personal fees from Fabre, grants and personal fees from Sanofi, outside the submitted work.

Dr. Fargnoli reports grants, personal fees and non-financial support from Almirall, grants and personal fees from Leo Pharma, grants and personal fees from Janssen, grants, personal fees and non-financial support from Novartis, personal fees from Lilly, grants and personal fees from Sanofi, personal fees from UCB, personal fees from Abbvie, grants, personal fees and non-financial support from AMGEN, personal fees from Pierre Fabre, grants and personal fees from Galderma, personal fees from Sun Pharma, personal fees from BMS, personal fees from Kyowa Kyirin, personal

fees from Pfizer, personal fees from MSD, outside the submitted work.

Dr. Forsea has nothing to disclose.

Dr. Grob reports personal fees from Amgen, personal fees from MSD, personal fees from Novartis, grants and personal fees from Pierre Fabre, grants and personal fees from BMS, personal fees from Philogen, personal fees from Roche, personal fees from Sanofi, outside the submitted work.

Dr. Hoeller reports personal fees from Amgen, personal fees from Almirall, personal fees from BMS, personal fees from MSD, personal fees from Novartis, personal fees from Pierre Fabre, personal fees from Roche, personal fees from Sanofi, outside the submitted work.

Dr. Kaufmann reports grants from Abbvie, grants from Almirall, grants from Amgen, grants from Astra Zeneca, grants from Biontech, grants from BMS, grants from BMS, grants from Celgene, grants from InflaRx, grants from Leo, grants from Lilly, grants from MSD, grants from Novartis, grants from Pfizer, grants from Pierre Fabre, grants from Regeneron, grants from Roche, grants from Sanofi, grants from UCB, outside the submitted work.

Dr. Kelleners-Smeets has nothing to disclose.

Dr. Lallas reports grants and personal fees from Sanofi, outside the submitted work.

Dr. Lebbé reports grants and personal fees from Bristol-Myers Squibb, personal fees from MSD, personal fees from Novartis, personal fees from Amgen, grants and personal fees from Roche, personal fees from Avantis Medical Systems, personal fees from Pierre Fabre, personal fees from Pfizer, personal fees from Incyte, outside the submitted work.

Dr. Lytvynenko has nothing to disclose.

Dr. Malvey reports grants and personal fees from Amgen, personal fees from MSD, grants and personal fees from Novartis, grants and personal fees from BMS, grants and personal fees from Almirall, personal fees from Sunpharma, personal fees from Pierre Fabre, outside the submitted work.

Dr. Moreno-Ramirez has nothing to disclose.

Dr. Nathan reports personal fees from BMS, personal fees from MSD, personal fees from Novartis, personal fees from Pfizer, grants and personal fees from Immunocore, personal fees from 4SC, outside the submitted work.

Dr. Pellacani reports personal fees from Novartis, personal fees from Sanofi, grants from Novartis, instruments from 3Gen, Vidix, Fotofinder and MAVIG GmbH, outside the submitted work.

Dr. Saiag reports personal fees from Amgen, personal fees from MSD, grants and personal fees from Novartis, grants and personal fees from NeraCare, grants and personal fees from BMS, grants and personal fees from Roche, grants and personal fees from Sanofi,

personal fees from Pierre Fabre/array, outside the submitted work.

Dr. Stratigos reports personal fees from Sanofi, personal fees from Janssen CILAG, personal fees and non-financial support from Novartis, grants from Genesis Pharma, grants from Abbvie, grants and personal fees from BMS, personal fees from Regeneron, grants from Leo-Pharma, grants from Lilly, outside the submitted work.

Dr. Van Akkooi reports grants and personal fees from Amgen, personal fees from Bristol-Myers Squibb, personal fees from Novartis, personal fees from MSD-Merck, grants and personal fees from Merck-Pfizer, personal fees from Pierre Fabre, personal fees from Sanofi, personal fees from Sirius Medical, personal fees from 4SC, outside the submitted work.

Dr. Vieira reports personal fees from BMS, outside the submitted work.

Dr. Zalaudek reports personal fees from Philogen, personal fees from MSD, personal fees from Novartis, personal fees from Sanofi, personal fees from La Roche Posay, personal fees from Sunpharma, personal fees from Biogen, personal fees from Cieffe Derma, outside the submitted work.

Dr. Lorigan has nothing to disclose.

References

- [1] Eggermont AM, Spatz A, Robert C. Cutaneous melanoma. *Lancet* 2014;383:816–27.
- [2] Saiag P, Bosquet L, Guillot B, Verola O, Avril MF, Bailly C, et al. Management of adult patients with cutaneous melanoma without distant metastasis. 2005 update of the French Standards, Options and Recommendations guidelines. Summary report. *Eur J Dermatol : EJD*. 2007;17:325–31.
- [3] Hauschild A, Rosien F, Lischner S. Surgical standards in the primary care of melanoma patients. *Onkologie* 2003;26:218–22.
- [4] Martin 2nd RC, Scoggins CR, Ross MI, Reintgen DS, Noyes RD, Edwards MJ, et al. Is incisional biopsy of melanoma harmful? *Am J Surg* 2005;190:913–7.
- [5] Pflugfelder A, Weide B, Eigentler TK, Forschner A, Leiter U, Held L, et al. Incisional biopsy and melanoma prognosis: Facts and controversies. *Clin Dermatol* 2010;28:316–8.
- [6] Ahmadi O, Das M, Hajarizadeh B, Mathy JA. Impact of shave biopsy on diagnosis and management of cutaneous melanoma: a systematic review and meta-analysis. *Ann Surg Oncol* 2021;28:6168–76.
- [7] Coit DG, Andtbacka R, Bichakjian CK, Dilawari RA, Dimaio D, Guild V, et al. Melanoma. *J Natl Compr Cancer Netw : JNCCN*. 2009;7:250–75.
- [8] SaNZGGW TeCAaACN. Australian cancer network melanoma guidelines revision working party. In: *Clinical practice guidelines for the management of melanoma in Australia and New Zealand*; 2008.
- [9] Negrier S, Saiag P, Guillot B, Verola O, Avril MF, Bailly C, et al. Guidelines for clinical practice: standards, options and recommendations 2005 for the management of adult patients exhibiting an M0 cutaneous melanoma, full report. National Federation of cancer campaign centers. French dermatology society. Update of the 1995 consensus conference and the 1998 standards, options, and recommendations. *Annales de dermatologie et de venerologie* 2005;132(10):S3–85.
- [10] Marsden JR, Newton-Bishop JA, Burrows L, Cook M, Corrie PG, Cox NH, et al. Revised U.K. guidelines for the management of cutaneous melanoma 2010. *Br J Dermatol* 2010;163:238–56.
- [11] Garbe C, Hauschild A, Volkenandt M, Schadendorf D, Stolz W, Reinhold U, et al. Evidence-based and interdisciplinary consensus-based German guidelines: systemic medical treatment of melanoma in the adjuvant and palliative setting. *Melanoma Res* 2008;18:152–60.
- [12] Hayes AJ, Maynard L, Coombes G, Newton-Bishop J, Timmons M, Cook M, et al. Wide versus narrow excision margins for high-risk, primary cutaneous melanomas: long-term follow-up of survival in a randomised trial. *Lancet Oncol* 2016;17:184–92.
- [13] Wheatley K, Wilson JS, Gaunt P, Marsden JR. Surgical excision margins in primary cutaneous melanoma: a meta-analysis and Bayesian probability evaluation. *Cancer Treat Rev* 2016;42:73–81.
- [14] Gillgren P, Drzewiecki KT, Niin M, Gullestad HP, Hellborg H, Mansson-Brahme E, et al. 2-cm versus 4-cm surgical excision margins for primary cutaneous melanoma thicker than 2 mm: a randomised, multicentre trial. *Lancet (London, England)* 2011;378:1635–42.
- [15] Hanna S, Lo SN, Saw RP. Surgical excision margins in primary cutaneous melanoma: a systematic review and meta-analysis. *Eur J Surg Oncol* 2021;47:1558–74. the journal of the European Society of Surgical Oncology and the British Association of Surgical Oncology.
- [16] Onkologie L. Leitlinienprogramm Onkologie (Deutsche Krebsgesellschaft, Deutsche Krebshilfe, AWMF): Diagnostik, Therapie und Nachsorge des Melanoms, Langversion 3.1. 2018. AWMF Registernummer: 032/024OL, [http://www.leitlinienprogramm-onkologie.de/leitlinien/melanom/\(abgerufenam: 05.11.2019\)](http://www.leitlinienprogramm-onkologie.de/leitlinien/melanom/(abgerufenam: 05.11.2019)).
- [17] Pflugfelder A, Kochs C, Blum A, Capellaro M, Czeschik C, Dettenborn T, et al. Malignant melanoma S3-guideline “diagnosis, therapy and follow-up of melanoma”. *J Dtsch Dermatol Ges* 2013;11(Suppl 6):1–116. 1–26.
- [18] Moehrle M, Dietz K, Garbe C, Breuninger H. Conventional histology vs. three-dimensional histology in lentigo maligna melanoma. *Br J Dermatol* 2006;154:453–9.
- [19] Tzellos T, Kyrgidis A, Mocellin S, Chan AW, Pilati P, Apalla Z. Interventions for melanoma in situ, including lentigo maligna. *Cochrane Database Syst Rev* 2014;Cd010308.
- [20] de Vries K, Greveling K, Prens LM, Munte K, Koljenovic S, van Doorn MB, et al. Recurrence rate of lentigo maligna after micrographically controlled staged surgical excision. *Br J Dermatol* 2016;174:588–93.
- [21] Hilari H, Llorca D, Traves V, Villanueva A, Serra-Guillen C, Requena C, et al. Conventional surgery compared with slow Mohs micrographic surgery in the treatment of lentigo maligna: a retrospective study of 62 cases. *Actas Dermo-Sifiliográficas* 2012;103:614–23.
- [22] Krausz AE, Higgins 2nd HW, Etkorn J, Sobanko J, Shin T, Giordano C, et al. Systematic review of technical variations for Mohs micrographic surgery for melanoma. *Dermatol Surg* 2021;47:1539–44.
- [23] Tio D, van der Woude J, Prinsen CAC, Jansma EP, Hoekzema R, van Montfrans C. A systematic review on the role of imiquimod in lentigo maligna and lentigo maligna melanoma: need for standardization of treatment schedule and outcome measures. *J Eur Acad Dermatol Venereol : JEADV* 2017;31:616–24.
- [24] Swetter SM, Chen FW, Kim DD, Egbert BM. Imiquimod 5% cream as primary or adjuvant therapy for melanoma in situ, lentigo maligna type. *J Am Acad Dermatol* 2015;72:1047–53.
- [25] Lallas A, Moscarella E, Kittler H, Longo C, Thomas L, Zalaudek I, et al. Real-world experience of off-label use of

- imiquimod 5% as an adjuvant therapy after surgery or as a monotherapy for lentigo maligna. *Br J Dermatol* 2021;185:675–7.
- [26] Buettiker UV, Yawalkar NY, Braathen LR, Hunger RE. Imiquimod treatment of lentigo maligna: an open-label study of 34 primary lesions in 32 patients. *Arch Dermatol* 2008;144:943–5.
- [27] Mahoney MH, Joseph MG, Temple C. Topical imiquimod therapy for lentigo maligna. *Ann Plast Surg* 2008;61:419–24.
- [28] Cotter MA, McKenna JK, Bowen GM. Treatment of lentigo maligna with imiquimod before staged excision. *Dermatol Surg* 2008;34:147–51. official publication for American Society for Dermatologic Surgery [et al].
- [29] Yelamos O, Cordova M, Blank N, Kose K, Dusza SW, Lee E, et al. Correlation of handheld reflectance confocal microscopy with radial video mosaicing for margin mapping of lentigo maligna and lentigo maligna melanoma. *JAMA dermatology* 2017;153:1278–84.
- [30] Moehrle M, Metzger S, Schippert W, Garbe C, Rassner G, Breuninger H. “Functional” surgery in subungual melanoma. *Dermatol Surg* 2003;29:366–74. official publication for American Society for Dermatologic Surgery [et al].
- [31] Breuninger H, Schlagenhauff B, Stroebel W, Schaumburg-Lever G, Rassner G. Patterns of local horizontal spread of melanomas: consequences for surgery and histopathologic investigation. *Am J Surg Pathol* 1999;23:1493–8.
- [32] Temple CL, Arlette JP. Mohs micrographic surgery in the treatment of lentigo maligna and melanoma. *J Surg Oncol* 2006;94:287–92.
- [33] Morton DL, Wen DR, Wong JH, Economou JS, Cagle LA, Storm FK, et al. Technical details of intraoperative lymphatic mapping for early stage melanoma. *Arch Surg* 1992;127:392–9 (Chicago, Ill : 1960).
- [34] Gershenwald JE, Scolyer RA, Hess KR, Sondak VK, Long GV, Ross MI, et al. Melanoma staging: evidence-based changes in the American Joint Committee on Cancer eighth edition cancer staging manual. *CA: a cancer journal for clinicians* 2017;67:472–92.
- [35] Thompson JF, Shaw HM. Sentinel node mapping for melanoma: results of trials and current applications. *Surg Oncol Clin* 2007;16:35–54.
- [36] Morton DL, Cochran AJ, Thompson JF, Elashoff R, Essner R, Glass EC, et al. Sentinel node biopsy for early-stage melanoma: accuracy and morbidity in MSLT-I, an international multicenter trial. *Ann Surg* 2005;242:302–11. discussion 11–3.
- [37] Faries MB, Thompson JF, Cochran AJ, Andtbacka RH, Mozzillo N, Zager JS, et al. Completion dissection or observation for sentinel-node metastasis in melanoma. *N Engl J Med* 2017;376:2211–22.
- [38] Wong SL, Faries MB, Kennedy EB, Agarwala SS, Akhurst TJ, Ariyan C, et al. Sentinel lymph node biopsy and management of regional lymph nodes in melanoma: American society of clinical oncology and society of surgical oncology clinical practice guideline update. *J Clin Oncol* 2018;36:399–413. official journal of the American Society of Clinical Oncology.
- [39] Cordeiro E, Gervais MK, Shah PS, Look Hong NJ, Wright FC. Sentinel lymph node biopsy in thin cutaneous melanoma: a systematic review and meta-analysis. *Ann Surg Oncol* 2016;23:4178–88.
- [40] Morton DL, Thompson JF, Cochran AJ, Mozzillo N, Elashoff R, Essner R, et al. Sentinel-node biopsy or nodal observation in melanoma. *N Engl J Med* 2006;355:1307–17.
- [41] Morton DL, Thompson JF, Cochran AJ, Mozzillo N, Nieweg OE, Roses DF, et al. Final trial report of sentinel-node biopsy versus nodal observation in melanoma. *N Engl J Med* 2014;370:599–609.
- [42] Leiter U, Stadler R, Mauch C, Hohenberger W, Brockmeyer N, Berking C, et al. Complete lymph node dissection versus no dissection in patients with sentinel lymph node biopsy positive melanoma (DeCOG-SLT): a multicentre, randomised, phase 3 trial. *Lancet Oncol* 2016;17:757–67.
- [43] Leiter U, Stadler R, Mauch C, Hohenberger W, Brockmeyer NH, Berking C, et al. Final analysis of DeCOG-SLT trial: No survival benefit for complete lymph node dissection in patients with melanoma with positive sentinel node. *J Clin Oncol* 2019;Jco1802306. official journal of the American Society of Clinical Oncology.
- [44] Farrow NE, Raman V, Williams TP, Nguyen KY, Tyler DS, Beasley GM. Adjuvant therapy is effective for melanoma patients with a positive sentinel lymph node biopsy who Forego completion lymphadenectomy. *Ann Surg Oncol* 2020;27:5121–5.
- [45] Torphy RJ, Friedman C, Ho F, Leonard LD, Thieu D, Lewis KD, et al. Adjuvant therapy for stage III melanoma without immediate completion lymph node dissection. *Ann Surg Oncol* 2021;29:806–15.
- [46] Morton DL, Wanek L, Nizze JA, Elashoff RM, Wong JH. Improved long-term survival after lymphadenectomy of melanoma metastatic to regional nodes. Analysis of prognostic factors in 1134 patients from the John Wayne Cancer Clinic. *Ann Surg* 1991;214:491–9. discussion 9–501.
- [47] Andtbacka RH, Kaufman HL, Collichio F, Amatruda T, Senzer N, Chesney J, et al. Talimogene laherparepvec improves durable response rate in patients with advanced melanoma. *J Clin Oncol* 2015;33:2780–8. official journal of the American Society of Clinical Oncology.
- [48] Lienard D, Eggermont AM, Koops HS, Kroon B, Towse G, Hiemstra S, et al. Isolated limb perfusion with tumour necrosis factor-alpha and melphalan with or without interferon-gamma for the treatment of in-transit melanoma metastases: a multicentre randomized phase II study. *Melanoma Res* 1999;9:491–502.
- [49] Deroose JP, Eggermont AM, van Geel AN, de Wilt JH, Burger JW, Verhoef C. 20 years experience of TNF-based isolated limb perfusion for in-transit melanoma metastases: TNF dose matters. *Ann Surg Oncol* 2012;19:627–35.
- [50] Weide B, Elsasser M, Buttner P, Pflugfelder A, Leiter U, Eigentler TK, et al. Serum markers lactate dehydrogenase and S100B predict independently disease outcome in melanoma patients with distant metastasis. *British journal of cancer* 2012;107:422–8.
- [51] Petersen RP, Hanish SI, Haney JC, Miller 3rd CC, Burfeind Jr WR, Tyler DS, et al. Improved survival with pulmonary metastasectomy: an analysis of 1720 patients with pulmonary metastatic melanoma. *J Thorac Cardiovasc Surg* 2007;133:104–10.
- [52] Sanki A, Scolyer RA, Thompson JF. Surgery for melanoma metastases of the gastrointestinal tract: indications and results. *Eur J Surg Oncol* 2009;35:313–9. the journal of the European Society of Surgical Oncology and the British Association of Surgical Oncology.
- [53] Chua TC, Saxena A, Morris DL. Surgical metastasectomy in AJCC stage IV M1c melanoma patients with gastrointestinal and liver metastases. *Ann Acad Med Singapore* 2010;39:634–9.
- [54] Wasif N, Bagaria SP, Ray P, Morton DL. Does metastasectomy improve survival in patients with Stage IV melanoma? A cancer registry analysis of outcomes. *J Surg Oncol* 2011;104:111–5.
- [55] Moschos SJ, Edington HD, Land SR, Rao UN, Jukic D, Shippe-Spotloe J, et al. Neoadjuvant treatment of regional stage IIIB melanoma with high-dose interferon alfa-2b induces objective tumor regression in association with modulation of tumor infiltrating host cellular immune responses. *J Clin Oncol* 2006;24:3164–71. official journal of the American Society of Clinical Oncology.
- [56] Farshad A, Burg G, Panizzon R, Dummer R. A retrospective study of 150 patients with lentigo maligna and lentigo maligna

- melanoma and the efficacy of radiotherapy using Grenz or soft X-rays. *Br J Dermatol* 2002;146:1042–6.
- [57] Burmeister BH, Henderson MA, Ainslie J, Fisher R, Di Iulio J, Smithers BM, et al. Adjuvant radiotherapy versus observation alone for patients at risk of lymph-node field relapse after therapeutic lymphadenectomy for melanoma: a randomised trial. *Lancet Oncol* 2012;13:589–97.
- [58] Henderson MA, Burmeister BH, Ainslie J, Fisher R, Di Iulio J, Smithers BM, et al. Adjuvant lymph-node field radiotherapy versus observation only in patients with melanoma at high risk of further lymph-node field relapse after lymphadenectomy (ANZMTG 01.02/TROG 02.01): 6-year follow-up of a phase 3, randomised controlled trial. *Lancet Oncol* 2015;16:1049–60.
- [59] Olivier KR, Schild SE, Morris CG, Brown PD, Markovic SN. A higher radiotherapy dose is associated with more durable palliation and longer survival in patients with metastatic melanoma. *Cancer* 2007;110:1791–5.
- [60] Rate WR, Solin LJ, Turrisi AT. Palliative radiotherapy for metastatic malignant melanoma: brain metastases, bone metastases, and spinal cord compression. *Int J Radiat Oncol Biol Phys* 1988;15:859–64.
- [61] Katz HR. The results of different fractionation schemes in the palliative irradiation of metastatic melanoma. *Int J Radiat Oncol Biol Phys* 1981;7:907–11.
- [62] Konefal JB, Emami B, Pilepich MV. Analysis of dose fractionation in the palliation of metastases from malignant melanoma. *Cancer* 1988;61:243–6.
- [63] Kirova YM, Chen J, Rabarijaona LI, Piedbois Y, Le Bourgeois JP. Radiotherapy as palliative treatment for metastatic melanoma. *Melanoma Res* 1999;9:611–3.
- [64] Long GV, Atkinson V, Lo S, Sandhu S, Guminski AD, Brown MP, et al. Combination nivolumab and ipilimumab or nivolumab alone in melanoma brain metastases: a multicentre randomised phase 2 study. *Lancet Oncol* 2018;19:672–81.
- [65] Tawbi H. Safety of nivolumab (NIVO) plus ipilimumab (IPI) in patients with advanced melanoma (MEL) metastatic to the brain: Initial Results From Phase 2 CheckMate 204. *SMR2016*.
- [66] Grimaldi AM, Simeone E, Giannarelli D, Muto P, Falivene S, Borzillo V, et al. Abscopal effects of radiotherapy on advanced melanoma patients who progressed after ipilimumab immunotherapy. *OncoImmunology* 2014;3:e28780.
- [67] Crittenden M, Kohrt H, Levy R, Jones J, Camphausen K, Dicker A, et al. Current clinical trials testing combinations of immunotherapy and radiation. *Semin Radiat Oncol* 2015;25:54–64.
- [68] Lehrer EJ, Peterson J, Brown PD, Sheehan JP, Quinones-Hinojosa A, Zaorsky NG, et al. Treatment of brain metastases with stereotactic radiosurgery and immune checkpoint inhibitors: an international meta-analysis of individual patient data. *Radiother Oncol* 2019;130:104–12. *Journal of the European Society for Therapeutic Radiology and Oncology*.
- [69] Rauschenberg R, Bruns J, Brutting J, Daubner D, Lohaus F, Zimmer L, et al. Impact of radiation, systemic therapy and treatment sequencing on survival of patients with melanoma brain metastases. *Eur J Cancer* 2019;110:11–20.
- [70] Tagliaferri L, Lancellotta V, Fionda B, Mangoni M, Casà C, Di Stefani A, et al. Immunotherapy and radiotherapy in melanoma: a multidisciplinary comprehensive review. *Hum Vaccines Immunother* 2021;1–8.
- [71] Ge Y, Che X, Gao X, Zhao S, Su J. Combination of radiotherapy and targeted therapy for melanoma brain metastases: a systematic review. *Melanoma Res* 2021;31:413–20.
- [72] Garsa A, Jang JK, Baxi S, Chen C, Akinniranye O, Hall O, et al. Radiation therapy for brain metastases: a systematic review. *Practical radiation oncology* 2021;11:354–65.
- [73] Brown PD, Ballman KV, Cerhan JH, Anderson SK, Carrero XW, Whitton AC, et al. Postoperative stereotactic radiosurgery compared with whole brain radiotherapy for resected metastatic brain disease (NCCTG N107C/CEC.3): a multicentre, randomised, controlled, phase 3 trial. *Lancet Oncol* 2017;18:1049–60.
- [74] Mahajan A, Ahmed S, McAleer MF, Weinberg JS, Li J, Brown P, et al. Post-operative stereotactic radiosurgery versus observation for completely resected brain metastases: a single-centre, randomised, controlled, phase 3 trial. *Lancet Oncol* 2017;18:1040–8.
- [75] Eggermont AM, Chiarion-Sileni V, Grob JJ, Dummer R, Wolchok JD, Schmidt H, et al. Adjuvant ipilimumab versus placebo after complete resection of high-risk stage III melanoma (EORTC 18071): a randomised, double-blind, phase 3 trial. *Lancet Oncol* 2015;16:522–30.
- [76] Weber J, Mandala M, Del Vecchio M, Gogas HJ, Arance AM, Cowey CL, et al. Adjuvant nivolumab versus ipilimumab in resected stage III or IV melanoma. *N Engl J Med* 2017;377:1824–35.
- [77] Long GV, Hauschild A, Santinami M, Atkinson V, Mandala M, Chiarion-Sileni V, et al. Adjuvant dabrafenib plus trametinib in stage III BRAF-mutated melanoma. *N Engl J Med* 2017;377:1813–23.
- [78] Eggermont AM, Chiarion-Sileni V, Grob JJ, Dummer R, Wolchok JD, Schmidt H, et al. Prolonged survival in stage III melanoma with ipilimumab adjuvant therapy. *N Engl J Med* 2016;375:1845–55.
- [79] Luke PR JJ, Queirolo P, Del Vecchio M, Mackiewicz J, Chiarion Sileni V, de la Cruz Merino L, et al. LBA3 PR - pembrolizumab versus placebo after complete resection of high-risk stage II melanoma: efficacy and safety results from the KEYNOTE-716 double-blind phase III trial. *Ann Oncol* 2021;32(suppl_5):S1283–346. 101016/annonc/annonc741. 2021.
- [80] Zimmer L, Livingstone E, Hassel JC, Fluck M, Eigentler T, Loquai C, et al. Adjuvant nivolumab plus ipilimumab or nivolumab monotherapy versus placebo in patients with resected stage IV melanoma with no evidence of disease (IMMUNED): a randomised, double-blind, placebo-controlled, phase 2 trial. *Lancet (London, England)* 2020;395:1558–68.
- [81] Long GV, Robert C, Butler MO, Couture F, Carlino MS, Day S, et al. Standard-dose pembrolizumab plus alternate-dose ipilimumab in advanced melanoma: KEYNOTE-029 cohort 1C, a phase 2 randomized study of two dosing schedules. *Clin Cancer Res* 2021;27:5280.
- [82] Pehamberger H, Soyer HP, Steiner A, Kofler R, Binder M, Mischer P, et al. Adjuvant interferon alfa-2a treatment in resected primary stage II cutaneous melanoma. *Austrian Malignant Melanoma Cooperative Group. J Clin Oncol* 1998;16:1425–9. *official journal of the American Society of Clinical Oncology*.
- [83] Garbe C, Radny P, Linse R, Dummer R, Gutzmer R, Ulrich J, et al. Adjuvant low-dose interferon {alpha}2a with or without dacarbazine compared with surgery alone: a prospective-randomized phase III DeCOG trial in melanoma patients with regional lymph node metastasis. *Ann Oncol* 2008;19:1195–201. *official journal of the European Society for Medical Oncology/ESMO*.
- [84] Kleeberg UR, Suciú S, Brocker EB, Rüter DJ, Chartier C, Lienard D, et al. Final results of the EORTC 18871/DKG 80-1 randomised phase III trial. rIFN-alpha2b versus rIFN-gamma versus ISCADOR M versus observation after surgery in melanoma patients with either high-risk primary (thickness >3 mm) or regional lymph node metastasis. *Eur J Cancer* 2004;40:390–402.
- [85] Hancock BW, Wheatley K, Harris S, Ives N, Harrison G, Horsman JM, et al. Adjuvant interferon in high-risk melanoma: the AIM HIGH Study—United Kingdom Coordinating Committee on Cancer Research randomized study of adjuvant low-dose extended-duration interferon Alfa-2a in high-risk resected

- malignant melanoma. *J Clin Oncol* 2004;22:53–61. official journal of the American Society of Clinical Oncology.
- [86] Cascinelli N, Belli F, MacKie RM, Santinami M, Bufalino R, Morabito A. Effect of long-term adjuvant therapy with interferon alpha-2a in patients with regional node metastases from cutaneous melanoma: a randomised trial. *Lancet (London, England)* 2001;358:866–9.
- [87] Cameron DA, Cornbleet MC, Mackie RM, Hunter JA, Gore M, Hancock B, et al. Adjuvant interferon alpha 2b in high risk melanoma - the Scottish study. *British journal of cancer* 2001;84:1146–9.
- [88] Kirkwood JM, Ibrahim JG, Sondak VK, Richards J, Flaherty LE, Ernstoff MS, et al. High- and low-dose interferon alfa-2b in high-risk melanoma: first analysis of intergroup trial E1690/S9111/C9190. *J Clin Oncol* 2000;18:2444–58. official journal of the American Society of Clinical Oncology.
- [89] Grob JJ, Dreno B, de la Salmoniere P, Delaunay M, Cupissol D, Guillot B, et al. Randomised trial of interferon alpha-2a as adjuvant therapy in resected primary melanoma thicker than 1.5 mm without clinically detectable node metastases. *French Cooperative Group on Melanoma. Lancet (London, England)* 1998;351:1905–10.
- [90] Hansson J, Aamdal S, Bastholt L, Brandberg Y, Hernberg M, Nilsson B, et al. Two different durations of adjuvant therapy with intermediate-dose interferon alfa-2b in patients with high-risk melanoma (Nordic IFN trial): a randomised phase 3 trial. *Lancet Oncol* 2011;12:144–52.
- [91] Eggermont AM, Suciú S, MacKie R, Ruka W, Testori A, Kruit W, et al. Post-surgery adjuvant therapy with intermediate doses of interferon alfa 2b versus observation in patients with stage IIb/III melanoma (EORTC 18952): randomised controlled trial. *Lancet (London, England)* 2005;366:1189–96.
- [92] Kirkwood JM, Strawderman MH, Ernstoff MS, Smith TJ, Borden EC, Blum RH. Interferon alfa-2b adjuvant therapy of high-risk resected cutaneous melanoma: the Eastern Cooperative Oncology Group Trial EST 1684. *J Clin Oncol* 1996;14:7–17. official journal of the American Society of Clinical Oncology.
- [93] Creagan ET, Dalton RJ, Ahmann DL, Jung SH, Morton RF, Langdon Jr RM, et al. Randomized, surgical adjuvant clinical trial of recombinant interferon alfa-2a in selected patients with malignant melanoma. *J Clin Oncol* 1995;13:2776–83. official journal of the American Society of Clinical Oncology.
- [94] Eggermont AM, Suciú S, Santinami M, Testori A, Kruit WH, Marsden J, et al. Adjuvant therapy with pegylated interferon alfa-2b versus observation alone in resected stage III melanoma: final results of EORTC 18991, a randomised phase III trial. *Lancet (London, England)* 2008;372:117–26.
- [95] Balch CM, Gershenwald JE, Soong S-J, Thompson JF, Atkins MB, Byrd DR, et al. Final version of 2009 AJCC melanoma staging and classification. *J Clin Oncol* 2009;27:6199–206. official journal of the American Society of Clinical Oncology.
- [96] Eggermont AMM, Chiarion-Sileni V, Grob JJ, Dummer R, Wolchok JD, Schmidt H, et al. Adjuvant ipilimumab versus placebo after complete resection of stage III melanoma: long-term follow-up results of the European Organisation for Research and Treatment of Cancer 18071 double-blind phase 3 randomised trial. *Eur J Cancer* 2019;119:1–10.
- [97] Ascierto PA, Del Vecchio M, Mandalá M, Gogas H, Arance AM, Dalle S, et al. Adjuvant nivolumab versus ipilimumab in resected stage IIIB-C and stage IV melanoma (CheckMate 238): 4-year results from a multicentre, double-blind, randomised, controlled, phase 3 trial. *Lancet Oncol* 2020;21:1465–77.
- [98] Eggermont AMM, Blank CU, Mandalá M, Long GV, Atkinson V, Dalle S, et al. Adjuvant pembrolizumab versus placebo in resected stage III melanoma. *N Engl J Med* 2018;378:1789–801.
- [99] Eggermont AM, Blank CU, Mandalá M, Long GV, Atkinson V, Dalle S, et al. Pembrolizumab versus placebo after complete resection of high-risk stage III melanoma: new recurrence-free survival results from the EORTC 1325-MG/Keynote 054 double-blinded phase III trial at three-year median follow-up. *J Clin Oncol* 2020;38:10000.
- [100] Eggermont CUB AMM, Mandalá M, Long GV, Victoria Atkinson V, Dalle S, Haydon AM, et al. LBA46 - pembrolizumab versus placebo after complete resection of high-risk stage III melanoma: final results regarding distant metastasis-free survival from the EORTC 1325-MG/Keynote 054 double-blinded phase III trial. *Ann Oncol* 2020;31(suppl_4):S1142–215. 101016/annonc/annonc325. 2020.
- [101] Eggermont AM, Meshcheryakov A, Atkinson V, Blank CU, Mandalá M, Long GV, et al. Crossover and rechallenge with pembrolizumab in recurrent patients from the EORTC 1325-MG/Keynote-054 phase 3 trial, pembrolizumab versus placebo after complete resection of high-risk stage III melanoma. *J Clin Oncol* 2021;39:9500.
- [102] Long GVSD, Del Vecchio M, et al. Adjuvant therapy with nivolumab combined with ipilimumab vs nivolumab alone in patients with resected stage IIIB-D/IV melanoma (CheckMate 915). In: *AACR Annual Meeting; 2021. Abstract CT004 Presented April 11, 2021. 2021.*
- [103] Maio M, Lewis K, Demidov L, Mandalá M, Bondarenko I, Ascierto PA, et al. Adjuvant vemurafenib in resected, BRAF(V600) mutation-positive melanoma (BRIM8): a randomised, double-blind, placebo-controlled, multicentre, phase 3 trial. *Lancet Oncol* 2018;19:510–20.
- [104] Hauschild A, Dummer R, Santinami M, Atkinson V, Mandalá M, Kirkwood JM, et al. Long-term benefit of adjuvant dabrafenib + trametinib (D+T) in patients (pts) with resected stage III BRAF V600-mutant melanoma: Five-year analysis of COMBI-AD. *J Clin Oncol* 2020;38:10001.
- [105] Atkinson V, Robert C, Grob J-J, Gogas H, Dutriaux C, Demidov LV, et al. Improved pyrexia-related outcomes associated with an adapted pyrexia adverse event (AE) management algorithm in patients (pts) treated with adjuvant dabrafenib + trametinib (dab + tram): primary results of COMBI-APlus. *J Clin Oncol* 2021;39:9525.
- [106] Hauschild A, Dummer R, Schadendorf D, Santinami M, Atkinson V, Mandalá M, et al. Longer follow-up confirms relapse-free survival benefit with adjuvant dabrafenib plus trametinib in patients with resected BRAF V600-mutant stage III melanoma. *J Clin Oncol* 2018;JCO1801219. official journal of the American Society of Clinical Oncology.
- [107] Menzies AM, Amaria RN, Rozeman EA, Huang AC, Tetzlaff MT, van de Wiel BA, et al. Pathological response and survival with neoadjuvant therapy in melanoma: a pooled analysis from the International Neoadjuvant Melanoma Consortium (INMC). *Nat Med* 2021;27:301–9.
- [108] Rozeman EA, Menzies AM, van Akkooi ACJ, Adhikari C, Bierman C, van de Wiel BA, et al. Identification of the optimal combination dosing schedule of neoadjuvant ipilimumab plus nivolumab in macroscopic stage III melanoma (OpACIN-neo): a multicentre, phase 2, randomised, controlled trial. *Lancet Oncol* 2019;20:948–60.
- [109] Amaria RN, Postow MA, Tetzlaff MT, Ross MI, Glitza IC, McQuade JL, et al. Neoadjuvant and adjuvant nivolumab (nivo) with anti-LAG3 antibody relatlimab (rela) for patients (pts) with resectable clinical stage III melanoma. *J Clin Oncol* 2021;39:9502.
- [110] Chapman PB, Hauschild A, Robert C, Haanen JB, Ascierto P, Larkin J, et al. Improved survival with vemurafenib in melanoma with BRAF V600E mutation. *N Engl J Med* 2011;364:2507–16.
- [111] Hodi FS, O'Day SJ, McDermott DF, Weber RW, Sosman JA, Haanen JB, et al. Improved survival with ipilimumab in patients with metastatic melanoma. *N Engl J Med* 2010;363:711–23.

- [112] Schadendorf D, van Akkooi ACJ, Berking C, Griewank KG, Gutzmer R, Hauschild A, et al. Melanoma. *The Lancet*. 2018; 392:971–84.
- [113] Amaral T, Seeber O, Mersi E, Sanchez S, Thomas I, Meiwes A, et al. Primary resistance to PD-1-based immunotherapy-A study in 319 patients with stage IV melanoma. *Cancers* 2020;12:1027.
- [114] Morton DLMN, Thompson JF, et al. An international, randomized, phase III trial of bacillus Calmette-Guerin (BCG) plus allogeneic melanoma vaccine (MCV) or placebo after complete resection of melanoma metastatic to regional or distant sites. *J Clin Oncol* 2007;8508. 25 ed.
- [115] Ko JM, Fisher DE. A new era: melanoma genetics and therapeutics. *J Pathol* 2011;223:241–50.
- [116] Sosman JA, Kim KB, Schuchter L, Gonzalez R, Pavlick AC, Weber JS, et al. Survival in BRAF V600-mutant advanced melanoma treated with vemurafenib. *N Engl J Med* 2012;366: 707–14.
- [117] Greger JG, Eastman SD, Zhang V, Bleam MR, Hughes AM, Smitheman KN, et al. Combinations of BRAF, MEK, and PI3K/mTOR inhibitors overcome acquired resistance to the BRAF inhibitor GSK2118436 dabrafenib, mediated by NRAS or MEK mutations. *Mol Cancer Therapeut* 2012;11:909–20.
- [118] Falchook GS, Long GV, Kurzrock R, Kim KB, Arkenau TH, Brown MP, et al. Dabrafenib in patients with melanoma, untreated brain metastases, and other solid tumours: a phase 1 dose-escalation trial. *Lancet* 2012;379:1893–901.
- [119] Long GV, Trefzer U, Davies MA, Kefford RF, Ascierto PA, Chapman PB, et al. Dabrafenib in patients with Val600Glu or Val600Lys BRAF-mutant melanoma metastatic to the brain (BREAK-MB): a multicentre, open-label, phase 2 trial. *Lancet Oncol* 2012;13:1087–95.
- [120] Robert C, Thomas L, Bondarenko I, O'Day S, Weber J, Garbe C, et al. Ipilimumab plus dacarbazine for previously untreated metastatic melanoma. *N Engl J Med* 2011;364:2517–26.
- [121] Champiat S, Lambotte O, Barreau E, Belkhir R, Berdelou A, Carbone F, et al. Management of immune checkpoint blockade dysimmune toxicities: a collaborative position paper. *Ann Oncol* 2016;27:559–74.
- [122] Haanen JBAG, Carbone F, Robert C, Kerr KM, Peters S, Larkin J, et al. Management of toxicities from immunotherapy: ESMO Clinical Practice Guidelines for diagnosis, treatment and follow-up. *Ann Oncol* 2017;28:iv119–i142.
- [123] Schadendorf D, Hodi FS, Robert C, Weber JS, Margolin K, Hamid O, et al. Pooled analysis of long-term survival data from phase II and phase III trials of ipilimumab in unresectable or metastatic melanoma. *J Clin Oncol* 2015;33:1889–94. official journal of the American Society of Clinical Oncology.
- [124] Robert C, Long GV, Brady B, Dutriaux C, Maio M, Mortier L, et al. Nivolumab in previously untreated melanoma without BRAF mutation. *N Engl J Med* 2014;372:320–30.
- [125] Hodi FS, Chiarion-Sileni V, Gonzalez R, Grob JJ, Rutkowski P, Cowey CL, et al. Nivolumab plus ipilimumab or nivolumab alone versus ipilimumab alone in advanced melanoma (CheckMate 067): 4-year outcomes of a multicentre, randomised, phase 3 trial. *Lancet Oncol* 2018;19:1480–92.
- [126] Hamid O, Robert C, Daud A, Hodi FS, Hwu WJ, Kefford R, et al. Five-year survival outcomes for patients with advanced melanoma treated with pembrolizumab in KEYNOTE-001. *Ann Oncol* 2019;30:582–8. official journal of the European Society for Medical Oncology/ESMO.
- [127] Long GV, Tykodi SS, Schneider JG, Garbe C, Gravis G, Rashford M, et al. Assessment of nivolumab exposure and clinical safety of 480 mg every 4 weeks flat-dosing schedule in patients with cancer. *Ann Oncol* 2018;29: 2208–13. official journal of the European Society for Medical Oncology/ESMO.
- [128] Lala M, Li M, Sinha V, de Alwis D, Chartash E, Jain L. A six-weekly (Q6W) dosing schedule for pembrolizumab based on an exposure-response (E-R) evaluation using modeling and simulation. *J Clin Oncol* 2018;36:3062.
- [129] Freshwater T, Kondic A, Ahamadi M, Li CH, de Greef R, de Alwis D, et al. Evaluation of dosing strategy for pembrolizumab for oncology indications. *Journal for immunotherapy of cancer* 2017;5:43.
- [130] Lala M, Li TR, de Alwis DP, Sinha V, Mayawala K, Yamamoto N, et al. A six-weekly dosing schedule for pembrolizumab in patients with cancer based on evaluation using modelling and simulation. *Eur J Cancer* 2020;131:68–75.
- [131] Larkin J, Chiarion-Sileni V, Gonzalez R, Grob J-J, Rutkowski P, Lao CD, et al. Five-year survival with combined nivolumab and ipilimumab in advanced melanoma. *N Engl J Med* 2019;381:1535–46.
- [132] Wolchok JD, Chiarion-Sileni V, Gonzalez R, Grob J-J, Rutkowski P, Lao CD, et al. CheckMate 067: 6.5-year outcomes in patients (pts) with advanced melanoma. *J Clin Oncol* 2021;39: 9506.
- [133] Lebbé C, Meyer N, Mortier L, Marquez-Rodas I, Robert C, Rutkowski P, et al. Evaluation of two dosing regimens for nivolumab in combination with ipilimumab in patients with advanced melanoma: results from the phase IIIb/IV CheckMate 511 trial. *J Clin Oncol* 2019;37:867–75.
- [134] Lebbé C, Meyer N, Mortier L, Marquez-Rodas I, Robert C, Rutkowski P, et al. Initial results from a phase IIIb/IV study evaluating two dosing regimens of nivolumab (NIVO) in combination with ipilimumab (IPI) in patients with advanced melanoma (CheckMate 511). *Ann Oncol* 2018;29:viii737.
- [135] Lebbe C, Meyer N, Mortier L, Marquez-Rodas I, Robert C, Rutkowski P, et al. Two dosing regimens of nivolumab (NIVO) plus ipilimumab (IPI) for advanced (adv) melanoma: three-year results of CheckMate 511. *J Clin Oncol* 2021;39:9516.
- [136] Wolchok JD, Chiarion-Sileni V, Gonzalez R, Rutkowski P, Grob J-J, Cowey CL, et al. Overall survival with combined nivolumab and ipilimumab in advanced melanoma. *N Engl J Med* 2017;377:1345–56.
- [137] Topalian SL, Hodi FS, Brahmer JR, Gettinger SN, Smith DC, McDermott DF, et al. Safety, activity, and immune correlates of anti-PD-1 antibody in cancer. *N Engl J Med* 2012;366:2443–54.
- [138] Robert C, Schachter J, Long GV, Arance A, Grob JJ, Mortier L, et al. Pembrolizumab versus ipilimumab in advanced melanoma. *N Engl J Med* 2015;372:2521–32.
- [139] Larkin J, Hodi FS, Wolchok JD. Combined nivolumab and ipilimumab or monotherapy in untreated melanoma. *N Engl J Med* 2015;373:1270–1.
- [140] Ascierto PA, McArthur GA, Dreno B, Atkinson V, Liskay G, Di Giacomo AM, et al. Cobimetinib combined with vemurafenib in advanced BRAF(V600)-mutant melanoma (coBRIM): updated efficacy results from a randomised, double-blind, phase 3 trial. *Lancet Oncol* 2016;17:1248–60.
- [141] Robert C, Grob JJ, Stroyakovskiy D, Karaszewska B, Hauschild A, Levchenko E, et al. Five-year outcomes with dabrafenib plus trametinib in metastatic melanoma. *N Engl J Med* 2019;381:626–36.
- [142] Grob JJ, Amonkar MM, Karaszewska B, Schachter J, Dummer R, Mackiewicz A, et al. Comparison of dabrafenib and trametinib combination therapy with vemurafenib monotherapy on health-related quality of life in patients with unresectable or metastatic cutaneous BRAF Val600-mutation-positive melanoma (COMBI-v): results of a phase 3, open-label, randomised trial. *Lancet Oncol* 2015;16:1389–98.
- [143] Dummer R, Ascierto PA, Gogas HJ, Arance A, Mandala M, Liskay G, et al. Encorafenib plus binimetinib versus vemurafenib or encorafenib in patients with BRAF-mutant melanoma (COLUMBUS): a multicentre, open-label, randomised phase 3 trial. *Lancet Oncol* 2018;19:603–15.
- [144] Ascierto PA, Dummer R, Gogas HJ, Flaherty KT, Arance A, Mandala M, et al. Update on tolerability and overall survival in

- COLUMBUS: landmark analysis of a randomised phase 3 trial of encorafenib plus binimetinib vs vemurafenib or encorafenib in patients with BRAF V600-mutant melanoma. *Eur J Cancer* 2020;126:33–44.
- [145] Ascierto PA, Dréno B, Larkin J, Ribas A, Liskay G, Maio M, et al. 5-Year outcomes with cobimetinib plus vemurafenib in BRAF (V600) mutation-positive advanced melanoma: extended follow-up of the coBRIM study. *Clin Cancer Res* 2021. an official journal of the American Association for Cancer Research.
- [146] Dummer R, Flaherty K, Robert C, Arance AM, Groot JWd, Garbe C, et al. Five-year overall survival (OS) in COLUMBUS: a randomized phase 3 trial of encorafenib plus binimetinib versus vemurafenib or encorafenib in patients (pts) with BRAF V600-mutant melanoma. *J Clin Oncol* 2021;39:9507.
- [147] Guo J, Si L, Kong Y, Flaherty KT, Xu X, Zhu Y, et al. Phase II, open-label, single-arm trial of imatinib mesylate in patients with metastatic melanoma harboring c-Kit mutation or amplification. *J Clin Oncol* 2011;29:2904–9. official journal of the American Society of Clinical Oncology.
- [148] Dummer R, Schadendorf D, Ascierto PA, Arance A, Dutriaux C, Di Giacomo AM, et al. Binimetinib versus dacarbazine in patients with advanced NRAS-mutant melanoma (NEMO): a multicentre, open-label, randomised, phase 3 trial. *Lancet Oncol* 2017;18:435–45.
- [149] Robert C, Karaszewska B, Schachter J, Rutkowski P, Mackiewicz A, Stroiakovski D, et al. Improved overall survival in melanoma with combined dabrafenib and trametinib. *N Engl J Med* 2015;372:30–9.
- [150] Long GV, Stroyakovsky DL, Gogas H, Levchenko E, de Braud F, Larkin JMG, et al. COMBI-d: a randomized, double-blinded, Phase III study comparing the combination of dabrafenib and trametinib to dabrafenib and trametinib placebo as first-line therapy in patients (pts) with unresectable or metastatic BRAFV600E/K mutation-positive cutaneous melanoma. *J Clin Oncol* 2014;32:9011.
- [151] Larkin J, Ascierto PA, Dreno B, Atkinson V, Liskay G, Maio M, et al. Combined vemurafenib and cobimetinib in BRAF-mutated melanoma. *N Engl J Med* 2014;371:1867–76.
- [152] Ribas A, Gonzalez R, Pavlick A, Hamid O, Gajewski TF, Daud A, et al. Combination of vemurafenib and cobimetinib in patients with advanced BRAF(V600)-mutated melanoma: a phase 1b study. *Lancet Oncol* 2014;15:954–65.
- [153] Dummer R, Ascierto PA, Gogas H, Arance AM, Mandalà M, Liskay G, et al. Overall survival in COLUMBUS: a phase 3 trial of encorafenib (ENCO) plus binimetinib (BINI) vs vemurafenib (VEM) or enco in BRAF-mutant melanoma. *J Clin Oncol* 2018;36:9504.
- [154] Dummer R, Arenberger P, Ascierto PA, De Groot JW, Hallmeyer S, Lotem M, et al. 1130TiP- NEMO: a phase 3 trial OF binimetinib (MEK162) versus dacarbazine IN patients with advanced NRAS-mutant melanoma who are untreated or have progressed after any number of immunotherapy regimens. *Ann Oncol* 2014;25(suppl 4):iv392.
- [155] Ugurel S, Röhmel J, Ascierto PA, Becker JC, Flaherty KT, Grob JJ, et al. Survival of patients with advanced metastatic melanoma: the impact of MAP kinase pathway inhibition and immune checkpoint inhibition - update 2019. *Eur J Cancer* 2020; 130:126–38.
- [156] Ascierto PA, Mandalà M, Ferrucci PF, Rutkowski P, Guidoboni M, Arance Fernandez AM, et al. LBA40 - SECOMBIT: the best sequential approach with combo immunotherapy ipilimumab (I)/nivolumab (N) and combo target therapy encorafenib (E)/binimetinib (B) in patients with BRAF mutated metastatic melanoma: a phase II randomized study. *Ann Oncol* 2021; 32(suppl_5):S1283–346. <https://doi.org/10.1016/annonc/annonc741>. 2021.
- [157] Atkins MB, Lee SJ, Chmielowski B, Ribas A, Tarhini AA, Truong T-G, et al. DREAMseq (doublet, randomized evaluation in advanced melanoma sequencing): a phase III trial—ECOG-ACRIN EA6134. *J Clin Oncol* 2021;39:356154.
- [158] Gogas HJ, Ribas A, Chesney J, Long GV, Kirkwood JM, Dummer R, et al. 10370 - MASTERKEY-265: a phase III, randomized, placebo (Pbo)-controlled study of talimogene laherparepvec (T) plus pembrolizumab (P) for unresectable stage IIIB–IVM1c melanoma (MEL). *Ann Oncol* 2021;32(suppl_5):S867–905. 101016/annonc/annonc706. 2021.
- [159] Andtbacka RHI, Collichio F, Harrington KJ, Middleton MR, Downey G, Öhring K, et al. Final analyses of OPTiM: a randomized phase III trial of talimogene laherparepvec versus granulocyte-macrophage colony-stimulating factor in unresectable stage III-IV melanoma. *Journal for immunotherapy of cancer* 2019;7:145.
- [160] Lipson EJ, Tawbi HA-H, Schadendorf D, Ascierto PA, Matamala L, Gutiérrez EC, et al. Relatlimab (RELA) plus nivolumab (NIVO) versus NIVO in first-line advanced melanoma: primary phase III results from RELATIVITY-047 (CA224-047). *J Clin Oncol* 2021;39:9503.
- [161] Hodi HAT FS, Lipson EJ, Schadendorf D, Ascierto PA, Matamala L, Gutiérrez EC, et al. 10360 - relatlimab (RELA) + nivolumab (NIVO) vs. NIVO in previously untreated metastatic or unresectable melanoma: additional efficacy in RELATIVITY-047. *Ann Oncol* 2021;32(suppl_5):S867–905. 101016/annonc/annonc706. 2021.
- [162] Goldinger SM, Buder-Bakhaya K, Lo SN, Forscher A, McKean M, Zimmer L, et al. Chemotherapy after immune checkpoint inhibitor failure in metastatic melanoma: a retrospective multicentre analysis. *Eur J Cancer* 2021;162:22–33.
- [163] Bedikian AY, DeConti RC, Conry R, Agarwala S, Papadopoulos N, Kim KB, et al. Phase 3 study of docosahexaenoic acid-paclitaxel versus dacarbazine in patients with metastatic malignant melanoma. *Ann Oncol* 2011;22:787–93. official journal of the European Society for Medical Oncology/ESMO.
- [164] Patel PM, Suci S, Mortier L, Kruit WH, Robert C, Schadendorf D, et al. Extended schedule, escalated dose temozolomide versus dacarbazine in stage IV melanoma: final results of a randomised phase III study (EORTC 18032). *Eur J Cancer* 2011;47:1476–83.
- [165] Bedikian AY, Millward M, Pehamberger H, Conry R, Gore M, Trefzer U, et al. Bcl-2 antisense (oblimersen sodium) plus dacarbazine in patients with advanced melanoma: the Oblimersen Melanoma Study Group. *J Clin Oncol* 2006;24:4738–45. official journal of the American Society of Clinical Oncology.
- [166] Middleton MR, Grob JJ, Aaronson N, Fierlbeck G, Tilgen W, Seiter S, et al. Randomized phase III study of temozolomide versus dacarbazine in the treatment of patients with advanced metastatic malignant melanoma. *J Clin Oncol* 2000;18:158–66. official journal of the American Society of Clinical Oncology.
- [167] Ringborg U, Rudenstam CM, Hansson J, Hafstrom L, Stenstam B, Strander H. Dacarbazine versus dacarbazine-vindesine in disseminated malignant melanoma: a randomized phase II study. *Med Oncol Tumor Pharmacother* 1989;6:285–9.
- [168] Chiarion Sileni V, Nortilli R, Aversa SM, Paccagnella A, Medici M, Corti L, et al. Phase II randomized study of dacarbazine, carmustine, cisplatin and tamoxifen versus dacarbazine alone in advanced melanoma patients. *Melanoma Res* 2001;11:189–96.
- [169] Young AM, Marsden J, Goodman A, Burton A, Dunn JA. Prospective randomized comparison of dacarbazine (DTIC) versus DTIC plus interferon-alpha (IFN-alpha) in metastatic melanoma. *Clin Oncol* 2001;13:458–65.
- [170] Bleehen NM, Newlands ES, Lee SM, Thatcher N, Selby P, Calvert AH, et al. Cancer Research Campaign phase II trial of temozolomide in metastatic melanoma. *J Clin Oncol* 1995;13: 910–3. official journal of the American Society of Clinical Oncology.
- [171] Jacquillat C, Khayat D, Banzet P, Weil M, Avril MF, Fumoleau P, et al. Chemotherapy by fotemustine in cerebral

- metastases of disseminated malignant melanoma. *Cancer Chemother Pharmacol* 1990;25:263–6.
- [172] Mornex F, Thomas L, Mohr P, Hauschild A, Delaunay MM, Lesimple T, et al. A prospective randomized multicentre phase III trial of fotemustine plus whole brain irradiation versus fotemustine alone in cerebral metastases of malignant melanoma. *Melanoma Res* 2003;13:97–103.
- [173] Rao RD, Holtan SG, Ingle JN, Croghan GA, Kottschade LA, Creagan ET, et al. Combination of paclitaxel and carboplatin as second-line therapy for patients with metastatic melanoma. *Cancer* 2006;106:375–82.
- [174] Verschraegen CF, Kleeberg UR, Mulder J, Rumke P, Truchetet F, Czarnetzki B, et al. Combination of cisplatin, vindesine, and dacarbazine in advanced malignant melanoma. A phase II study of the EORTC malignant melanoma cooperative group. *Cancer* 1988;62:1061–5.
- [175] Margolin K, Ernstoff MS, Hamid O, Lawrence D, McDermott D, Puzanov I, et al. Ipilimumab in patients with melanoma and brain metastases: an open-label, phase 2 trial. *Lancet Oncol* 2012;13:459–65.
- [176] Tawbi HA, Forsyth PA, Algazi A, Hamid O, Hodi FS, Moschos SJ, et al. Combined nivolumab and ipilimumab in melanoma metastatic to the brain. *N Engl J Med* 2018;379:722–30.
- [177] Margolin HAT KA, Forsyth PA, Hodi FS, Algazi A, Hamid O, Lao CD, et al. 1039MO - CheckMate 204: 3-year outcomes of treatment with combination nivolumab (NIVO) plus ipilimumab (IPI) for patients (pts) with active melanoma brain metastases (MBM). *Ann Oncol* 2021;32(suppl_5):S867–905. <https://doi.org/10.1016/annonc/annonc706>.
- [178] Long GV, Atkinson V, Lo S, Guminski AD, Sandhu SK, Brown MP, et al. Five-year overall survival from the anti-PD1 brain collaboration (ABC Study): randomized phase 2 study of nivolumab (nivo) or nivo+ipilimumab (ipi) in patients (pts) with melanoma brain metastases (mets). *J Clin Oncol* 2021;39:9508.
- [179] Davies MA, Saiag P, Robert C, Grob JJ, Flaherty KT, Arance A, et al. Dabrafenib plus trametinib in patients with BRAF(V600)-mutant melanoma brain metastases (COMBI-MB): a multicentre, multicohort, open-label, phase 2 trial. *Lancet Oncol* 2017;18:863–73.
- [180] Gaudy-Marqueste C, Carron R, Delsanti C, Loundou A, Monestier S, Archier E, et al. On demand Gamma-Knife strategy can be safely combined with BRAF inhibitors for the treatment of melanoma brain metastases. *Ann Oncol* 2014;25:2086–91. official journal of the European Society for Medical Oncology/ESMO.
- [181] Churilla TM, Chowdhury IH, Handorf E, Collette L, Collette S, Dong Y, et al. Comparison of local control of brain metastases with stereotactic radiosurgery vs surgical resection: a secondary analysis of a randomized clinical trial. *JAMA Oncol* 2019;5:243–7.
- [182] Amaral T, Kiecker F, Schaefer S, Stege H, Kaehler K, Terheyden P, et al. Combined immunotherapy with nivolumab and ipilimumab with and without local therapy in patients with melanoma brain metastasis: a DeCOG* study in 380 patients. *Journal for immunotherapy of cancer* 2020;8:e000333.
- [183] Galli G, Cavalieri S, Di Guardo L, Cimminiello C, Nichetti F, Corti F, et al. Combination of immunotherapy and brain radiotherapy in metastatic melanoma: a retrospective analysis. *Oncology research and treatment* 2019;42:186–94.
- [184] Gonzalez M, Hong AM, Carlino MS, Atkinson V, Wang W, Lo S, et al. A phase II, open label, randomized controlled trial of nivolumab plus ipilimumab with stereotactic radiotherapy versus ipilimumab plus nivolumab alone in patients with melanoma brain metastases (ABC-X Trial). *J Clin Oncol* 2019;37:TPS9600-TPS.
- [185] Marquez-Rodas I, Arance A, Berciano Guerrero MA, Díaz Beveridge R, Alamo MDC, García Castaño A, et al. 1038MO - intracranial activity of encorafenib and binimetinib followed by radiotherapy in patients with BRAF mutated melanoma and brain metastasis: preliminary results of the GEM1802/EBRAIN-MEL phase II clinical trial. *Ann Oncol* 2021;32(suppl_5):S867–905. <https://doi.org/10.1016/annonc/annonc706>.
- [186] Robert C, Ribas A, Schachter J, Arance A, Grob J-J, Mortier L, et al. Pembrolizumab versus ipilimumab in advanced melanoma (KEYNOTE-006): post-hoc 5-year results from an open-label, multicentre, randomised, controlled, phase 3 study. *Lancet Oncol* 2019;20:1239–51.
- [187] Pires da Silva I, Ahmed T, Reijers ILM, Weppeler AM, Betof Warner A, Patrinely JR, et al. Ipilimumab alone or ipilimumab plus anti-PD-1 therapy in patients with metastatic melanoma resistant to anti-PD-(L)1 monotherapy: a multicentre, retrospective, cohort study. *Lancet Oncol* 2021;22:836–47.
- [188] Rosenberg SA, Restifo NP. Adoptive cell transfer as personalized immunotherapy for human cancer. *Science (New York, NY)* 2015;348:62–8.
- [189] Chesney JA, Larkin JM, Kirkwood JM, Weber JS, Khushalani NI, Lewis K, et al. Abstract CT008: lifileucel (LN-144), a cryopreserved autologous tumor infiltrating lymphocyte (TIL) therapy in patients with advanced (unresectable or metastatic) melanoma: durable duration of response at 28 month follow up. *Cancer Res* 2021;81:CT008.
- [190] Arance AM, Cruz-Merino Ldl, Petrella TM, Jamal R, Ny L, Carneiro A, et al. Lenvatinib (len) plus pembrolizumab (pembro) for patients (pts) with advanced melanoma and confirmed progression on a PD-1 or PD-L1 inhibitor: updated findings of LEAP-004. *J Clin Oncol* 2021;39:9504.
- [191] Hilke FJ, Sinnberg T, Gschwind A, Niessner H, Demidov G, Amaral T, et al. Distinct mutation patterns reveal melanoma subtypes and influence immunotherapy response in advanced melanoma patients. *Cancers* 2020;12.
- [192] Cho KK, Cust AE, Foo YM, Long GV, Menzies AM, Eslick GD. Metastatic acral melanoma treatment outcomes: a systematic review and meta-analysis. *Melanoma Res* 2021;31:482–6.
- [193] Zheng Q, Li J, Zhang H, Wang Y, Zhang S. Immune checkpoint inhibitors in advanced acral melanoma: a systematic review. *Front Oncol* 2020;10:602705.
- [194] Gaiser MR, Skorokhod A, Gransheier D, Weide B, Koch W, Schif B, et al. Variables that influence BRAF mutation probability: a next-generation sequencing, non-interventional investigation of BRAFV600 mutation status in melanoma. *PLoS One* 2017;12:e0188602.
- [195] Teixeira C, Castillo P, Martinez-Vila C, Arance A, Alos L. Molecular markers and targets in melanoma. *Cells* 2021;10.
- [196] Nenclares P, Ap Dafydd D, Bagwan I, Begg D, Kerawala C, King E, et al. Head and neck mucosal melanoma: the United Kingdom national guidelines. *European Journal of Cancer* 2020;138:11–8.
- [197] Smith HG, Bagwan I, Board RE, Capper S, Coupland SE, Glen J, et al. Ano-uro-genital mucosal melanoma UK national guidelines. *Eur J Cancer* 2020;135:22–30.
- [198] Shoushtari AN, Wagstaff J, Ascierto PA, Butler MO, Lao CD, Marquez-Rodas I, et al. CheckMate 067: long-term outcomes in patients with mucosal melanoma. *J Clin Oncol* 2020;38:10019.
- [199] Nathan P, Cohen V, Coupland S, Curtis K, Damato B, Evans J, et al. Uveal melanoma UK national guidelines. *Eur J Cancer* 2015;51:2404–12.
- [200] Heppt MV, Amaral T, Kähler KC, Heinzerling L, Hassel JC, Meissner M, et al. Combined immune checkpoint blockade for metastatic uveal melanoma: a retrospective, multi-center study. *Journal for immunotherapy of cancer* 2019;7:299.
- [201] Nathan P, Hassel JC, Rutkowski P, Baurain J-F, Butler MO, Schlaak M, et al. Overall survival benefit with tebentafusp in metastatic uveal melanoma. *N Engl J Med* 2021;385:1196–206.
- [202] Ny L, Jespersen H, Karlsson J, Alsén S, Filges S, All-Eriksson C, et al. The PEMDAC phase 2 study of pembrolizumab and

- entinostat in patients with metastatic uveal melanoma. *Nat Commun* 2021;12:5155.
- [203] Owen CN, Shoushtari AN, Chauhan D, Palmieri DJ, Lee B, Rohaan MW, et al. Management of early melanoma recurrence despite adjuvant anti-PD-1 antibody therapy. *Ann Oncol* 2020; 31:1075–82.
- [204] Versluis AMH JM, Weppler A, Brown L, de Joode K, Suijkerbuijk KPM, Zimmer L, et al. 1080MO - the value of local therapy in treatment of solitary melanoma progression upon immune checkpoint inhibition. *Ann Oncol* 2020;31(suppl_4): S672–710. 101016/annonc/annonc280. 2020.